



12 Lead ECGs: Ischemia, Injury, Infarction

This course has been awarded
four (4) contact hours.
This course expires on October 22, 2018.

Copyright © 2015 by RN.com.
All Rights Reserved. Reproduction and distribution
of these materials are prohibited without the
express written authorization of RN.com.

First Published: April 10, 2003
Revised: June 7, 2005
Revised: June 7, 2007
Revised: October 22, 2015

Acknowledgements

[RN.com](#) acknowledges the valuable contributions of...

Tanna R. Thomason, MS, RN, CCRN

Karen Siroky, MSN, RN

Lindsey Ryan, MSN, RN, CCRN-K, ACNS-BC

Before Continuing This Course

If you are new at ECG rhythm interpretation, take [RN.com](https://www.rn.com)'s course "Telemetry Interpretation" before beginning this course.

This course will not teach basic ECG interpretation, bundle branch block, axis deviation, or chamber hypertrophies.

Purpose and Objectives

The purpose of 12 Lead ECG Interpretation: Ischemia, Injury, and Infarction is to educate healthcare professionals on a systematic system of examining and interpreting 12 lead ECGs. The course also offers information about basic treatments in various situations and potential problems that may be encountered.

After successful completion of this continuing education course, participants will be able to:

1. Identify demographic data pertaining to the severity of coronary artery disease and occurrence of acute myocardial infarctions.
2. Correctly identify the following normal ECG components: isoelectric line, Q wave, R wave, and ST segment.
3. Describe the ECG characteristics of a normal 12 lead ECG.
4. Systematically assess and interpret a 12 lead ECG for abnormal patterns of ischemia, injury, and infarction.
5. Interpret ST elevation MI (STEMI or acute injury changes).
6. Describe potential treatment options for the patient experiencing acute myocardial damage.
7. Differentiate STEMI from non-STEMI and contrast the treatment priorities for each.

This self-learning module is designed for the nurse who has **already mastered basic ECG rhythm interpretation** and is ready to advance into the interpretation of the 12 lead ECG. This module will not teach basic ECG interpretation and dysrhythmias.

In this module, the emphasis will be on the identification and management of acute ischemia, injury, and infarction. The module teaches the bedside practitioner to examine the 12-lead ECG in a systematic format to determine acute or chronic changes. ST Elevation MI (STEMI) infarction patterns will be discussed for the patient experiencing acute injury to the inferior, anterior, and lateral surfaces of the heart. Non-ST elevation myocardial infarction (Non-STEMI) patterns and treatments will also be discussed.

After correctly identifying the 12-lead ECG abnormality, this module helps the nurse to determine nursing priorities in managing patients with specific types of infarctions. Treatment options per the American College of Cardiology (ACC) and American Heart Association (AHA) will be integrated throughout the sections.

Introduction

Accurate 12 lead electrocardiogram (ECG) interpretation is an essential diagnostic tool when caring for the patient with clinical symptoms of a suspected acute coronary syndrome (ACS). If your patient is admitted with a diagnosis of unstable angina, chest pain, or rule-out myocardial infarction, the 12 Lead ECG is used as a focal point in treatment decision strategies.

- Would your patient benefit from a **thrombolytic** agent?
- Should your patient go directly to the **cardiac catheterization** lab for a percutaneous coronary intervention (e.g. angioplasty/stent)?
- Is **drug therapy** (e.g. anticoagulation, nitroglycerin) and medical management best for your patient?

You and the physician will collaborate in these types of critical decisions. To expedite appropriate treatment, all nurses working in the critical care setting, emergency department, urgent care, and cardiovascular cath lab areas must be able to detect patterns of acute ischemia, injury and infarction on the 12 lead ECG.

Angina, STEMI, NSTEMI

ACS is comprised of one of three conditions:

Unstable angina -

- Occurs without cause (for example, it wakes you up from sleep).
- Lasts longer than 15 - 20 minutes.
- Responds poorly to nitroglycerin.
- May occur along with a drop in blood pressure or significant shortness of breath (Medline, 2015).

NSTEMI - (Non-ST Segment Elevation Myocardial Infarction)

- ST Segment Elevation does not occur.
- Coronary artery is only partially blocked.
- A smaller portion of cardiac tissue dies, since there is not complete artery blockage.
- Difficult to distinguish from unstable angina without measuring cardiac enzymes.

STEMI - (ST Elevation Myocardial Infarction)

- ST elevation does occur indicating complete blockage of the coronary artery.
- A larger amount of cardiac tissue dies.
- More severe than NSTEMI.
- Early intervention critical.

Regions of Myocardial Involvement

The nature and severity of an acute myocardial infarction (MI) is related to the region of myocardial involvement. The three most common regions of the heart affected by an MI (STEMI or NSTEMI) include:

- Inferior
- Anterior
- Lateral

Knowledge of ECG tracings and coronary artery source that is specific to each of these regions is vital. Additionally, the nurse must be aware of the clinical signs and symptoms of an MI as well as the potential complications, all of which are vital to patient care management.

Acute Myocardial Infarction Statistics

In 2011, 375,295 Americans died of coronary heart disease. Each year, an estimated 635,000 Americans have an initial heart attack (defined as first hospitalized myocardial infarction or coronary heart disease death) and approximately 300,000 have a recurrent attack. It is estimated that an additional 155,000 silent first myocardial infarctions occur each year. Approximately every 34 seconds, 1 American has a coronary event, and approximately every 1 minute 24 seconds, an American will die of one (Mozaffarian, Benjamin, Go, Arnett, Blaha, Cushman, ... & Stroke, 2015). Of the people who die from heart attacks, about half died within an hour of the first symptoms and before they reach a healthcare facility (National Heart, Lung and Blood Institute, 2015).

Prognosis is based on variables including size and depth of MI, blood supply to residual non-infarcted myocardium (collateral circulation), age of patient, number of previous infarctions, and left ventricular function.

The average age at the time of the first MI is 50 years for men and 60 years for women. Early recognition and treatment is essential. It has been shown that early treatment results in reductions in mortality, infarct size, and improved left ventricular function. Reperfusion therapy beyond 12 hours from onset of symptoms has shown little benefit.

Knowledge Check 1

Reperfusion therapy shows little benefit if started _____ hours after the onset of symptoms.

- a. 4- Incorrect! Reperfusion therapy shows little benefit if started 12 hours after the onset of symptoms.
- b. 6- Incorrect! Reperfusion therapy shows little benefit if started 12 hours after the onset of symptoms.
- c. 12- Correct!**
- d. 14- Incorrect! Reperfusion therapy shows little benefit if started 12 hours after the onset of symptoms.

Symptomatology

Chest discomfort or pain associated with MI is called angina pectoris. Unstable angina can occur at rest or with exercise. It may result from a sudden decrease in coronary blood flow caused by:

- coronary thrombosis
- coronary spasm
- inability to increase coronary blood flow sufficiently to meet myocardial oxygen demands (e.g. during exercise)

Acute myocardial infarction is the actual necrosis of myocardial tissue as a result of decreased blood supply to the myocardium. Most acute MIs are caused by atherosclerosis (e.g. fat deposits, fibrosis, calcification, and/or platelet aggregation), which results in a progressive narrowing of the coronary artery. Narrowing of the coronary artery can then lead to thrombus formation and ultimately impede blood flow. Occlusion can be caused also by coronary artery spasm. The site of the infarction is determined by the location of the coronary artery occlusion.

According to the World Health Organization (WHO) definition, the diagnosis of MI is based on the presence of at least two of the following:

- Clinical history of ischemic-type chest discomfort
- Changes on serially obtained electrocardiographic tracings
- Rise and fall in serum cardiac marker labs

Clues to Help Diagnose Chest Pain

The comprehensive assessment of the patient experiencing chest discomfort (or other questionable symptoms) centers around three assessment categories:

- physical exam
- 12 lead ECG
- cardiac marker labs

Although all three categories are important, the 12 lead ECG is THE primary diagnostic tool.

Assessment Clues

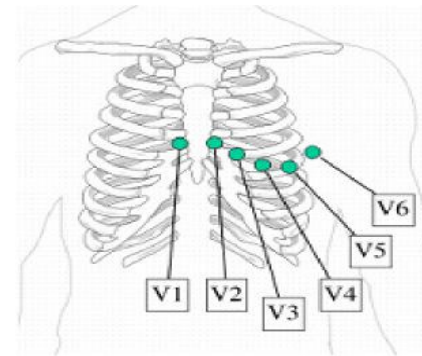
- Physical Exam
- 12 lead ECG
- Cardiac Markers

Format of the Printed 12 Lead ECG

The 12 Lead ECG has a standardized format. There are six Frontal Leads which are labeled or called Leads I, II, III, aVR, aVL, and aVF.

Leads I, II, and III represent a picture of the heart's electrical conduction from viewpoint of the limb to the heart.

12 Lead Format			
I	aVR	V1	V4
II	aVL	V2	V5
III	aVF	V3	V6



Example of precordial lead placement.

The small "a" means "Augmented". The augmented leads show the electrical conduction (augmented) from the heart to the:

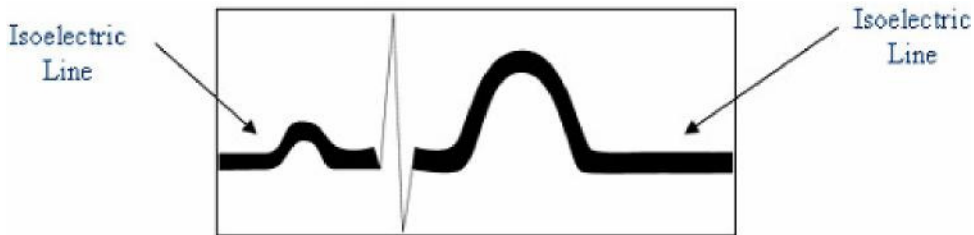
- right arm (aVR)
- left arm (aVL)
- right foot (aVF)

There are six Precordial Leads (also called "Chest Leads" or "V leads") named V1, V2, V3, V4, V5, and V6.

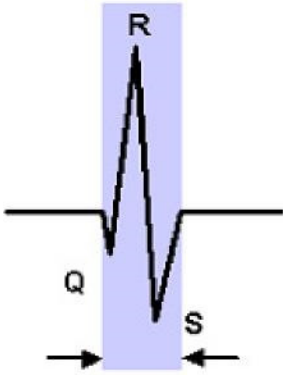
The “Isoelectric Line” – What Is It and Why Is It Important?

The isoelectric line is the baseline on the ECG recording. It is where electrical activity is "resting".

The isoelectric line is an imaginary line on the ECG recording where your PR interval is recorded and where the ST segment normally sits. The isoelectric line is important because it is used as a normal reference point for evaluating ST and T wave abnormalities.



Review of Basic ECG Morphology

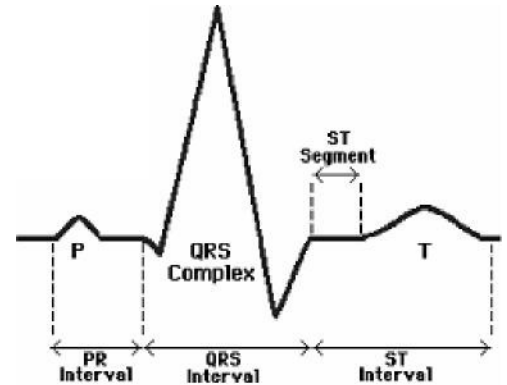


The QRS interval is measured from start of Q to end of S.

Atrial depolarization is represented by the “P” wave. The impulse travels from the sinoatrial (SA) node into the atrio-ventricular node (AV node) to the Bundle of His. This conduction is reflected in the PR interval.

Ventricular **depolarization** is represented by the QRS tracing. Depolarization of the heart ventricles occurs almost simultaneously, via the Bundle of His and Purkinje fibers.

The ST segment is a reflection of ventricular **repolarization**, which is followed by the T wave, which shows repolarization of the ventricles. Remember the ST segment should also sit on the isoelectric line.



Used with permission from Smart Med Ed.

QRS Terminology

If you need a quick review of the basic ECG terminology, study the table below. It is very important that we “speak the same language” related to identification of Q waves, ST segments, and T waves.

COPYRIGHT INFORMATION: "SinusRhythmLabels" by Created by Agateller (Anthony Atkielski), converted to svg by atom. - en:Image:SinusRhythmLabels.png. Licensed under Public Domain via Commons -

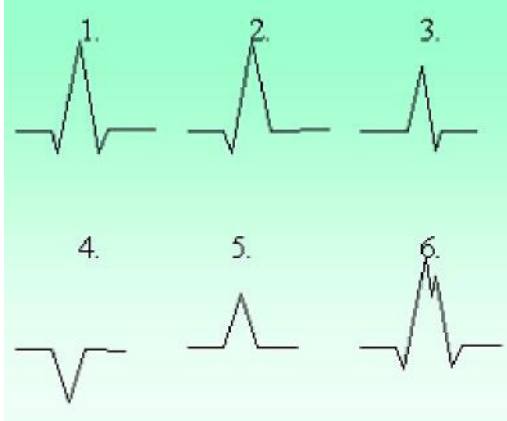
<https://commons.wikimedia.org/wiki/File:SinusRhythmLabels.svg#/media/File:SinusRhythmLabels.svg>

More Information

Term	Definition
Q wave	First negative deflection after the PR interval
R wave	Any upright deflection
S wave	A negative deflection after the R wave
QS	All of the complex is negative
Qrs	“Lower case” letters when complexes are small (this is subjective, either is fine)
QRS	“Upper case” letters when complexes are large

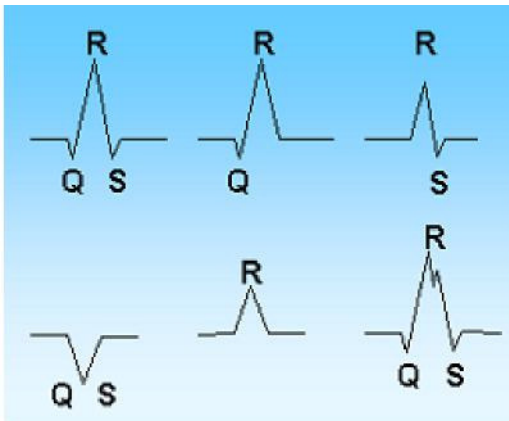
QRS Morphology Interpretation

Practice interpreting the following QRS morphologies



Used with permission from Smart Med Ed.

Answer:



1. QRS
2. qR
3. Rs
4. QS
5. R
6. QRS with "notched" appearance

Normal Q Waves

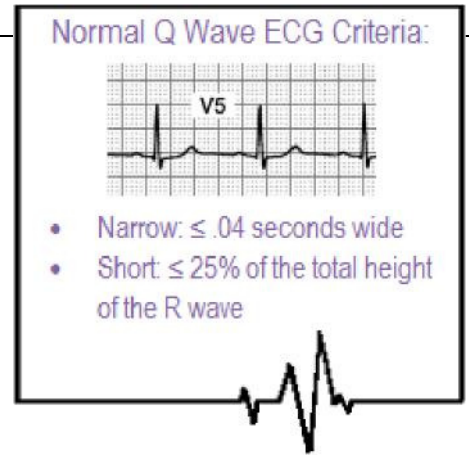
Normal Q waves are an indication of normal septal depolarization. After the atria depolarize, the septum depolarizes, followed by the right and left bundle branches. The leads which have the “best view” of the septum are leads I, aVL, V5, and V6. When the septum depolarizes, the ECG records this event with a small “Q wave.”

These small or “baby” Qs are called “normal septal Q waves” and they have two important ECG criteria:

- Normal septal Q's need to be < one small ECG box in width (.04 seconds wide)
- Normal septal Q's need to be < one-fourth the height of the R wave

For example, if the R wave is 6 boxes high and the preceding Q wave is one box deep, this would be $\leq 25\%$ the height of the R wave.

Normal septal Q's can be seen in any of the 12 leads, but are often best seen in Leads I, aVL, V5, and V6. Regardless of the lead they are found in, they must meet both ECG criteria to be considered “normal.”



Abnormal Q Waves

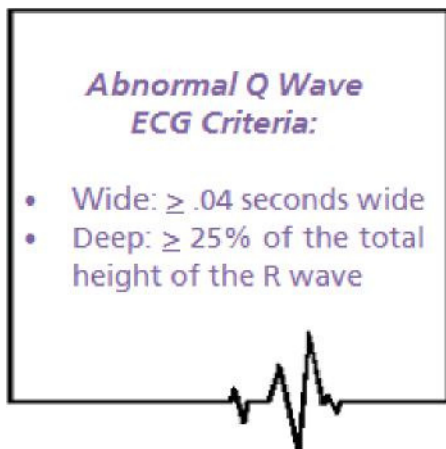
Normal Qs are skinny and not very deep.

Abnormal Q waves are an indication that the heart has been damaged and cannot conduct normally. Abnormal Q waves reflect that there has been a loss of electrical activity resulting from damaged myocardial tissue.

Abnormal Q waves are a permanent marker of damage and never go away. Abnormal Qs can be found in any of the 12 leads. Generally speaking, the larger the number of leads with abnormal Qs, the greater the amount of heart damage!

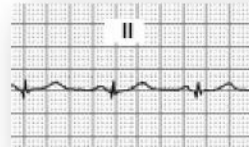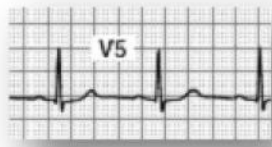
An abnormal Q wave has the following criteria:

- $\geq .04$ seconds wide
- $\geq 25\%$ the height of the R wave
- Permanent (do not go away) on the ECG recording



Samples of Q Waves

Additional
Samples of
**Normal
Q Waves:**

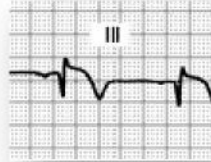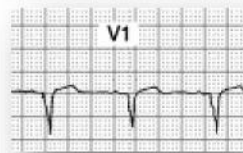


Remember, small Q waves can be normal in lead

II

Samples of **Abnormal Q Waves:**

Abnormal QS
morphology
no R wave present

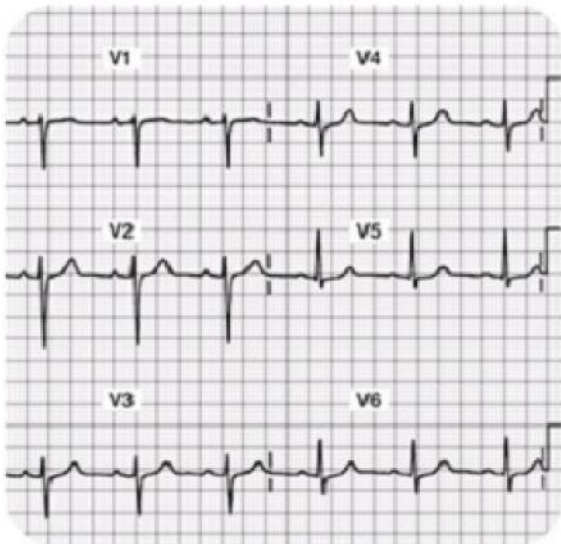


Note also the
ST segment
elevation

More Information:

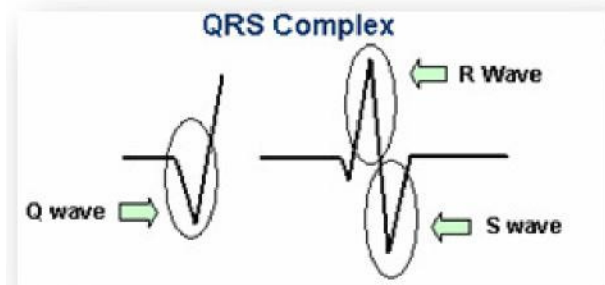
Abnormal Q's are wider and deeper than the normal Q wave. Abnormal Q waves indicate this person has experienced heart damage and as a result, there is a loss of electrical conduction due to old tissue damage. These Q waves are permanent and typically do not go away with time.

Normal R Waves



Note the R wave progression in leads V1-V4.

There should be an R wave in each of the 12 leads except in lead aVR. Some R waves are very short (for example in V1 the r wave is “tiny,” but it is present, so it counts!).



Normal R waves become progressively higher in amplitude from V1 through V4, then stabilize or gradually become smaller again through V6. Some people call this “Normal R Wave **Progression.**”

Poor R Wave Progression

An old anterior myocardial infarction can cause poor R wave progression. In this setting, there is no R wave in the anterior precordial leads and instead Q waves are present.

The causes of poor R wave progression include:

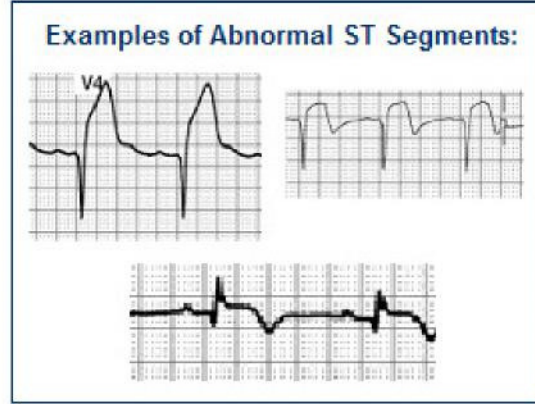
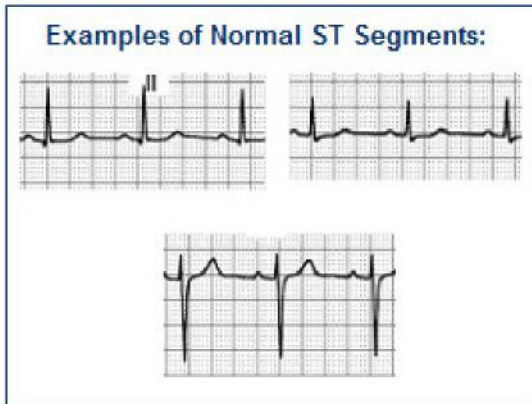
1. Old anterior myocardial infarction
2. Lead misplacement (frequently in obese women)
3. Left bundle branch block or left anterior fascicular block
4. Left ventricular hypertrophy
5. WPW syndrome
6. Dextrocardia
7. Tension pneumothorax with mediastinal shift
8. Congenital heart disease

Introduction to S-T Segments

Observe the ST segment and junction point (J-point) morphology. The J-point is located at the end of the QRS where the T wave begins.

- The ST segment should be isoelectric (e.g. neither negative, positive, nor biphasic).
- To be clinically significant the ST deviation from the isoelectric line should be greater than 1-2mm

(Exceptions: V1 and aVR have abnormal looking ST segments)



More information to follow about the significance of S-T segments

The Normal 12 lead ECG

Before you can interpret “abnormal,” you must be able to identify the “normal” 12 lead ECG. Examine all 12 Leads closely with the exception of aVR. The aVR lead is not useful in the detection of ischemia, injury, and infarction.

There are four basic items you will want to examine and assess using this process:

Step 1: Go on a “Q wave search”

- Q waves should be $\leq .04$ seconds wide and $\leq 25\%$ the height of the R wave. These normal septal q waves are typically seen best in leads I, aVL, V5, and V6. Circle all Q waves which do not meet the above criteria.

Step 2: Go on an “R wave search”

- 11 out of the 12 leads should have an “R wave.” The only lead which does not have an R wave is aVR. Some leads have tiny R waves... For example in V1, the R wave is very small, but if there is an upright deflection after the PR interval, we call it an R wave. Circle all leads which do not have an R wave, as this would be abnormal.

Step 3: Examine the ST segment... does it live on the isoelectric line?

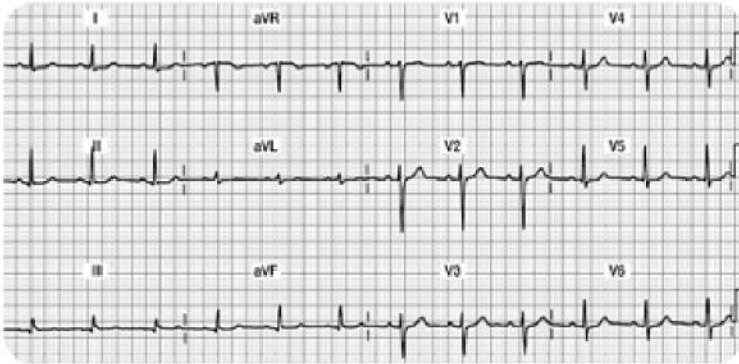
- With the exception of V1, all eleven leads should have the ST segment begin and end on the isoelectric baseline. Mark any leads that have a ST segment that does not begin and end on the isoelectric line.

Step 4: Examine the T wave...

- T waves should be upright in all eleven leads except it might be biphasic in V1 (which is normal). Circle any T waves that are not upright.

The 12 Lead Checklist

This is an example of a **normal 12 Lead**

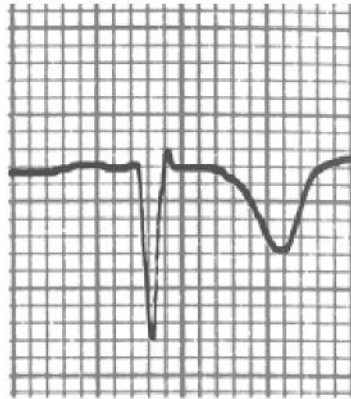
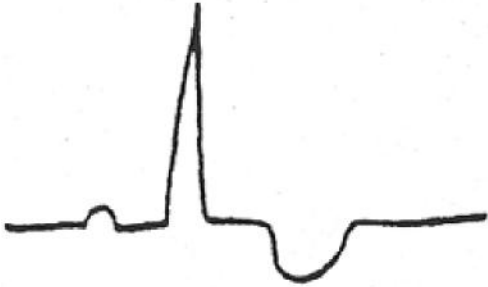


- Go on a “Q wave search”
 - *Are the Q waves $\leq .04$ seconds wide and $\leq 25\%$ the height of the R wave?* You might see small Q waves in Lead II, III, aVF, V5, and V6. These identified Q waves meet the “normal” criteria & simply record that the septum had normal depolarization.
- Go on an “R wave search”
 - *11 out of the 12 leads should have an “R wave.”* The only lead which does not have an R wave is aVR. Notice how V1 has a tiny R wave. Also, note how the R wave “grows” or gets taller as the ECG progresses from V1 through V6. This progressive height of the R wave is called, “normal R wave progression.” If you find normal R wave progression, you can rest assured that this part of the myocardium is healthy.
- Examine the ST segment... does it live on the isoelectric line?
 - With the exception of V1 (which is sometimes biphasic), all eleven leads should have the ST segment begin and end on the isoelectric baseline. Note that it is normal in V2 and V3 for the ST segment to quickly transition into the T wave, thus making it a bit more difficult to critique.
- Examine the T wave
 - The T waves should be upright in all eleven leads, with the exception of V1, which might be biphasic (also a normal finding).

Ischemic Injury and Infarction Myocardial Ischemia

Ischemia is defined as a temporary deprivation of myocardial oxygenation resulting in ST segment and/or T wave inversion on the ECG. The ST-T wave abnormalities typically return to the normal ST on the isoelectric line and upright T wave position when the myocardial oxygen supply meets the demand.

Ischemia: see example below of transient ST-T wave abnormalities with associated myocardial oxygen deprivation.



Ischemia, Injury, and Infarction Scenario One:

Your patient is experiencing midsternal chest pressure, an eight (8) on a scale of 0-10. You obtain a 12 lead ECG. You note that several of the T waves are inverted on this ECG tracing. You ask the patient to remain supine as you apply oxygen at 2 liters per nasal cannula, attach a cardiac monitor, and obtain IV access. Your nursing goals are to:

- Decrease oxygen demands
- Increase oxygen supply to the myocardium

The healthcare provider orders nitroglycerin (NTG) .0.4mg sublingual. NTG dilates coronary arteries and increases myocardial oxygen delivery.

The patient's blood pressure is 146/90, so you proceed with administering the nitroglycerin. A few minutes later, the patient's chest pain is gone and blood pressure is stable. **You obtain a second, follow-up 12 lead ECG. The T waves have returned to their upright, normal position.** This is an example of ischemia... not a MI, but clearly a warning sign. If the ischemia is not resolved, it can progress into an acute MI.

Knowledge Check 2

Inverted T waves that have returned to their upright normal position after you have administered nitroglycerin 1.4mg x 3 indicate infarction.

- a. True
- b. False**

Scenario Two:

Your patient has left your unit to undergo a diagnostic stress test on a treadmill. After increasing the speed and incline on the treadmill, the staff note new ST segment depression and T wave inversion on the 12 lead ECG recording. The treadmill is immediately stopped.

The patient rests and oxygen is applied. The abnormal ST-T waves return upright to the normal position.

This is an abnormal treadmill stress test where the patient will likely need a coronary angiogram (cardiac catheterization) to determine the extent of coronary artery disease. This patient may ultimately need percutaneous coronary intervention (angioplasty or stent) or possibly coronary artery bypass grafting surgery (CABG).

Knowledge Check 3

Your patient is having a stress test when you notice a new onset of ST segment depression and T wave inversion. You will:

- a. Continue with the treadmill.
- b. Stop the treadmill immediately, apply oxygen to the patient and have them rest.-Correct!**
- c. Continue with the treadmill if the patient is not complaining of any pain.
- d. Stop the treadmill and administer lidocaine.

What about Cardiac Markers

Common cardiac markers include CK, CK-MB, and Troponin I. These three lab tests will be elevated in the setting of acute myocardial tissue damage.

The previous scenarios are examples of temporary myocardial oxygen deprivation resulting in abnormal ST –T waves on the ECG, called myocardial “ischemia.”

In these situations, the patient is not having a ST elevation myocardial infarction (STEMI). If the above patients were to have cardiac marker lab tests drawn (Troponin I and or CK-MB lab tests) during these episodes, the markers would NOT be elevated because actual myocardial cell damage has not occurred.

Knowledge Check 4

Ischemic T wave inversions seen on the ECG may return to the “upright” (normal) position when the patient’s oxygen supply meets the oxygen demands.

a. True- Correct!

b. False- Incorrect! T wave inversions may be transient (and may return upright) after oxygen demands are minimized and supply is optimized.

Ischemia is a Warning Sign

Ischemia is a WARNING SIGN and is typically accompanied with chest discomfort. Whenever you see new ST- T wave inversion in any lead, assess your patient for cardiac symptoms and always think about oxygen supply and demand. Follow standing protocols or specific MD orders, but always remember that you want to:

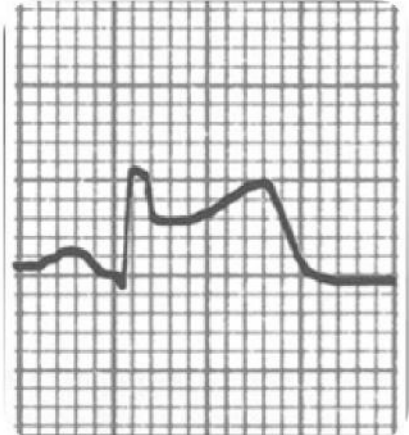
- Increase oxygen supply
- Decrease oxygen demands
- Communicate findings to provider

Myocardial Injury

Acute myocardial injury is characterized by ST segment elevation, or STEMI, due to acute damage of myocardial tissues.

With myocardial injury, the more leads displaying ST elevation, the larger the infarct **size**. **With acute ST elevation, myocardial tissue destruction is occurring right before your very eyes!!**

Think about the principles of oxygen supply and demand.
How can you decrease demand and increase supply?



MONA

Immediate treatment typically includes morphine, oxygen, nitroglycerin and aspirin (MONA).

Morphine Sulfate: Morphine sulfate is the analgesic of choice for the management of chest pain associated with STEMI. Administer in 2 – 4 mg IV repeated at 5- to 15-minute intervals until pain is relieved. Assess blood pressure (BP) and respiratory rate (RR) closely.

Oxygen: Supplemental oxygen should be administered to patients with oxygen desaturation and to all patients with uncomplicated STEMI during the first 6 hours.

Nitroglycerin: Patients with ongoing ischemic discomfort should receive sublingual nitroglycerin (0.4 mg) every 5 minutes for a total of 3 doses, after which an assessment should be performed to examine the need for intravenous nitroglycerin. Always follow your organization's protocol and physician orders.

Aspirin: Aspirin should be chewed by patients who have not taken aspirin before presenting with STEMI. The initial dose should be 162 mg which is more effective than the dose of 325 mg.

More Information:

Warning... potential “drug-to-drug” interaction:

Before administering nitroglycerin, make sure your patient's blood pressure is above 90 systolic AND make sure your patient has NOT taken any erectile dysfunction medication within the last 48 hours. If you administer nitroglycerin to a patient who has taken an erectile dysfunction medication recently, the nitroglycerin may cause a dangerous refractory hypotension!

In addition to MONA

In addition to MONA, evidence based practice shows there is great benefit from adding a beta blocker medication. If not contraindicated (low BP or heart rate), immediate beta-blocker therapy appears to reduce the magnitude of infarction and reduces life threatening ventricular tachyarrhythmias.

Additional treatment includes continuous ECG monitoring, ST-segment monitoring (if available) and rest. Stay in close communication with your patient's MD.

The MD will consider the appropriateness of:

Percutaneous coronary intervention (e.g. angioplasty/stent insertion) versus

Systemic thrombolytic treatment versus

Medical management (e.g. Heparin, nitroglycerin drip, beta blocker therapy)

Knowledge Check 5

Which of the following medication is shown to decrease the size of an infraction and reduce life-threatening tachyarrhythmias?

- a. Statins
- b. Beta-blockers- Correct!**
- c. Aspirin

Review of Cardiac Markers

You will recall that cardiac markers peak and return to normal at different times.

Refer to the table below for a review:

Normal Lab Values for Common Cardiac Markers

Lab Test	Normal Values
Creatine Kinase (CK) Total Value	0 - 170 IU/L
CK/MB	0 - 6 mg/ml
CK Index or Ratio	0 - 1.5%
Troponin I	< 0.4 ng/ml Borderline: .4 - 2 ng/ml Elevated: > 2 ng/ml

*Lab values vary slightly from facility to facility.
Your facility's normal values may be somewhat different.*

More Information:

Marker	Times to Initial Elevation (Hours)	Peak Hours	Return to Normal Range (Days)	Comment
Creatine Kinase (CK) Normal 0 -170 CK/MB Normal 0 -6	3 - 12	24	2 - 3	Elevated by non-cardiac etiologies (skeletal muscle injury)
CK/MB Ratio or Relative Index % MB Total CK value Normal 0- 1.5	3 - 12	24	2 - 3	
Troponin I Normal: <0.4 BL: 0.4-2.0 Elevated: >2	2 - 4	18 - 24	5 - 14	Not influenced by skeletal muscle trauma or renal failure
Myoglobin	1 - 2	4 - 8	1	Measured Q 1 Hr. x 3 used in Urgent Care or ER setting

What is the Nurses Role?

Acute STEMI is very dangerous as the patient is most likely to develop sudden death related to ventricular arrhythmias such as Ventricular Tachycardia (VT) and Ventricular Fibrillation (VF).

As a healthcare professional, you should:

- Assess and stabilize your patient. Assess for characteristics of chest pain and hemodynamic response (BP, heart rate & rhythm).
- Decrease myocardial oxygen demands while increasing supply.
- Obtain the stat 12 lead ECG. Looks for new ST-T wave elevations reflecting acute injury.
- Evaluate cardiac marker labs (Troponin I, CK, CK-MB, Myoglobin). Cardiac markers will be elevated if the patient is having damage to the myocardial tissue.
- Stay in close communication with the provider.

Knowledge Check 6


Acute ST elevation required immediate attention.

a. True- Correct!

b. False- Incorrect! New ST elevation is a sign of new myocardial injury and requires immediate attention.

Infarction

Infarction simply means “old damage.” Remember the deep and wide abnormal Q waves which develop when the heart muscle is damaged? These Q waves are permanent markers on the 12 lead. The reason why we see a deep and wide Q wave is because damaged/scarred myocardial tissue cannot conduct normally, resulting in an abnormal Q on the ECG.



Examples of abnormal Q waves which are deep and wide in relation to the R wave.

In addition to abnormal Q waves, the patient may lose some, or all, of the voltage (height) on the R wave. The small voltage R waves

are a result of dead tissue which cannot conduct the electrical impulse.

Abnormal Q waves usually develop within 1-4 days of an acute STEMI. Generally speaking, the greater the number of leads with abnormal Q waves, the greater the amount of damage.

However, the best way to assess cardiac function (and damaged areas) is with a two-dimensional echocardiogram (2-D Echo).

Conclusions: Permanent deep ($\geq 25\%$ height of the R wave) and wide ($\geq .04$ seconds) Q waves noted in two or more leads indicates damage through the layers of the myocardium. Scarred tissue cannot conduct electrical impulses normally, thus the ECG records this abnormality with deep and wide Q waves.

Knowledge Check 7

Abnormal Q waves indicate temporary damage has occurred in the myocardium.

- a. True- Incorrect! Abnormal Q waves indicate permanent damage has occurred in the myocardium. They develop within a few days of new STEMI and will remain for the lifetime of a patient.
- b. False- Correct!

Coronary Artery Blood Supply

Normal coronary artery blood flows through three main coronary arteries:

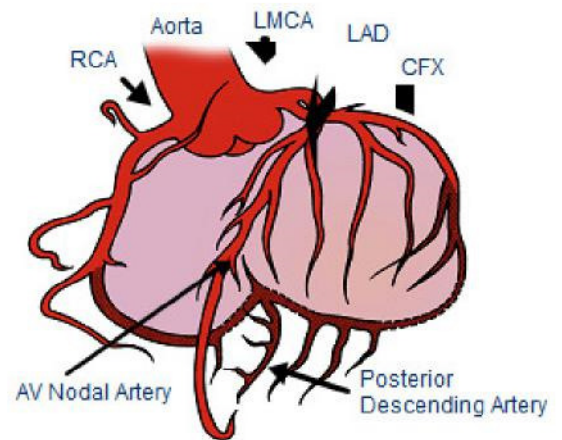
- Right Coronary Artery (RCA)
- Left Anterior Descending (LAD)
- Left Circumflex (LCx)

The RCA supplies blood and oxygen to the right atrium and right ventricle. The Left Coronary Artery has two major branches; they are called the Left Anterior Descending (LAD) and the Left Circumflex (LCx) coronary arteries. The LAD supplies blood and oxygen to the anterior portion of the left ventricle. The LCx supplies blood and oxygen to the lateral portion of the left ventricle.

Normal Coronary Artery Anatomy and Blood Flow

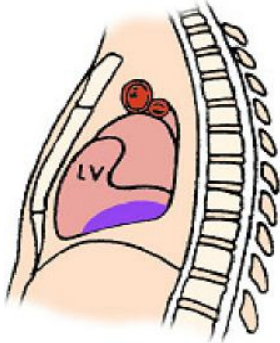
The Coronary Arteries and their Major Branches:

- Right Coronary Artery (RCA)
- Left Main Coronary Artery (LMCA)
- Left Anterior Descending (LAD) Coronary Artery
- Circumflex (CFX) Artery



Specific ST Elevation Myocardial Infarctions

This section will review three most common types of STEMIs which include the acute inferior, anterior, and lateral infarcts.



Used with permission
from Smart Med Ed.

Inferior Wall MI

The inferior wall of the myocardium is located on the surface of the myocardium above the diaphragm.

Coronary Artery Source

Acute inferior wall myocardial infarctions (IWMI) are classified as a STEMI and are generally the result of occlusion to the right coronary artery (RCA). Less frequently, they might be caused by disease in a dominant left circumflex artery. Inferior wall MIs are the most common type of infarct.

You need to know that the RCA supplies blood to several important structures including the AV node in 90% of the population, the Bundle of His, and the SA node in 55% of people. Therefore, when occlusion of the RCA, conduction defects may result producing AV blocks (example Type II or third degree heart block). The AV blocks are usually ischemic, transient, and reversible, but can require pacemaker therapy.

Right Coronary Artery Blood Supply

The Right Coronary Artery supplies blood to:

Right atrium.

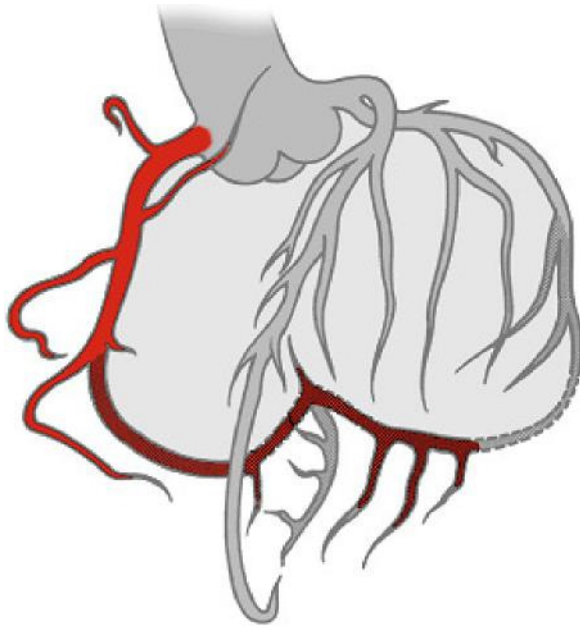
Right ventricle.

SA Node in 55% of population.

AV Node in 90% of population.

Posterior wall in 90% of population (described as "right dominant").

RCA feeds into the PDA (posterior descending artery) in 85% of population. PDA feeds inferior wall.



Used with permission
from Smart Med Ed.

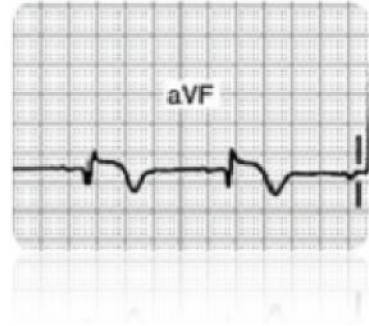
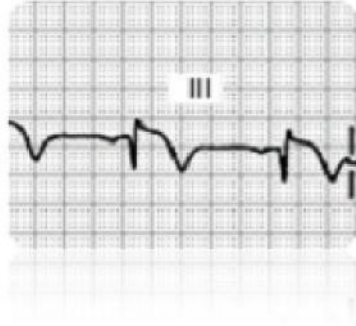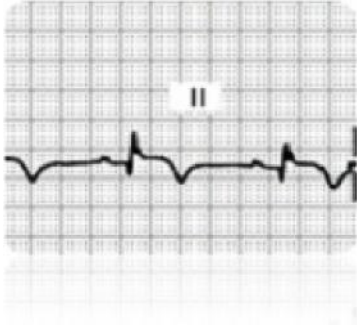
Knowledge Check 8

In the majority of the population, the right coronary artery supplies blood to the:

- a. Right atrium
- b. Right Ventricle
- c. AV node
- d. All of the above- Correct!**

ECG Findings with Inferior Wall MIs

Do you see changes in Lead II, III, or aVF?

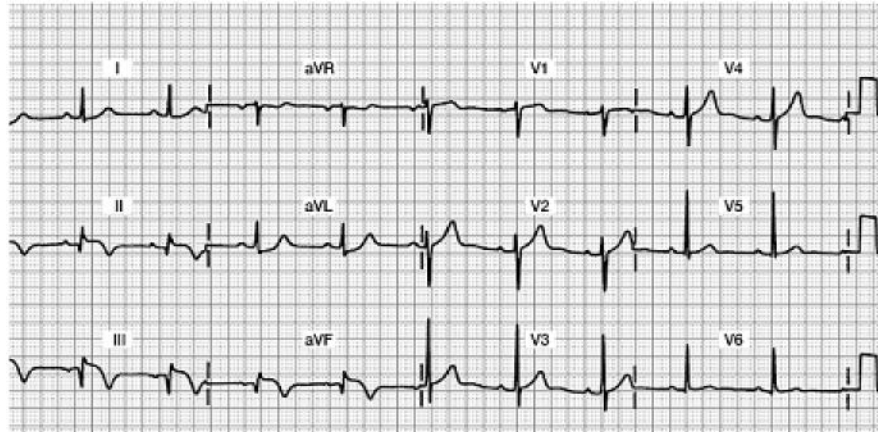


Acute Inferior Wall MI 12-Lead ECG

Focus on Leads II, III, and aVF

Do you see any abnormalities?

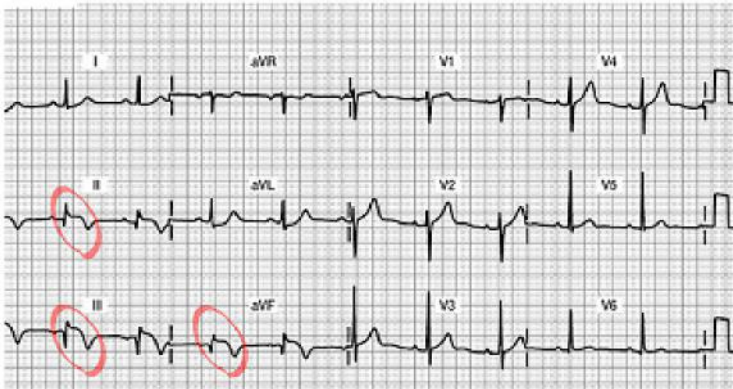
- Abnormal Q waves?
- Decreased R wave voltage?
- ST segment elevation?
- Inverted T waves?



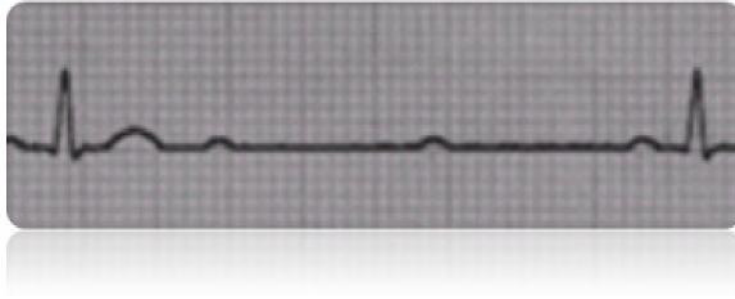
Acute Inferior Wall MI 12 Lead ECG

Do you see the 12 lead ECG abnormalities?

- Acute ST segment elevation in Leads II, III and aVF... this is a marker of “acute injury”
- Inverted T wave.... this will stay inverted for up to one month and will eventually return upright
- Abnormal Q’s in Leads III and aVF... this is the beginning of the deep and wide Q waves... they will likely grow deeper as the days progress.
- Decreased R wave voltage (as the Q’s grow deeper, the R’s get smaller... all the result of damaged myocardial tissue that is no longer able to conduct a normal impulse.



Potential Complications



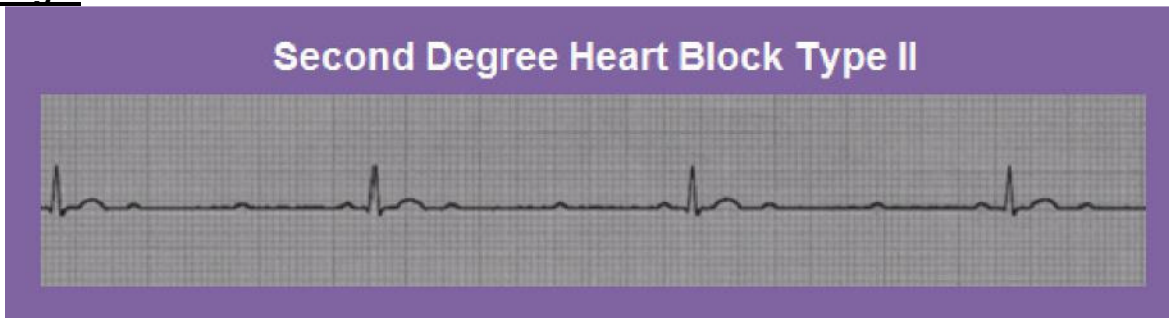
Potential complications of RCA occlusion with resulting inferior wall (IWMI) STEMI include:

- **Sinus node disturbances:** Watch for sinus bradycardia, sinus arrest, and sinus exit blocks.
- **AV block:** Parasympathetic hyperactivity is common with IWMI so watch for first, second (usually Type I), third degree conduction delays or “blocks” that may occur within hours or up through the first two days. AV conduction disturbances occur two to three times more frequently in inferior infarctions compared with anterior infarctions. Patients with a second or third degree AV block have a higher mortality rate.
- **Clinical Symptoms:** Nausea, vomiting and vasovagal syncope caused by enhanced vagal stimulation.
- **Suspect right ventricular damage:** The RCA also supplies the blood to the right ventricle (RV) in many individuals. Approximately one third of all inferior wall MI patients also have damage to the RV.

Early detection of RV infarction is important because therapy for right-sided heart failure is very different from therapy for left ventricular infarction. RV failure is usually treated with volume loading; whereas left ventricular failure is treated with preload reduction (e.g. diuretics, afterload reduction). RV infarction can be diagnosed with the ECG by using an additional three leads which are placed on the right side of the chest or “right precordial leads,” V4R, V5R, V6R, creating a 15 lead ECG.

Many experts feel patients with inferior wall MIs should routinely receive right precordial lead monitoring to detect potential RV infarction. The 15 lead ECG tracing is the standard of care at many hospitals. Other facilities may use 2-D echocardiograms to assess RV function.

Larger Image:

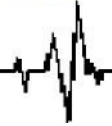

Management of Inferior Wall STEMI

- Collaborate with MD to evaluate patients' candidacy for thrombolytic therapy or percutaneous coronary intervention (PCI). If the patient is to receive a thrombolytic, the goal is to administer this drug within 30 minutes. If the goal is to send the patient to the cath lab for a PCI, the goal is to have this started within 90 minutes. Remember that "time is muscle," so we must work with the interdisciplinary team in a highly coordinated fashion.
- Routine post-MI care: pain relief, stress reduction, oxygen therapy, continuous monitoring for arrhythmias, heart and lung assessments.
- Monitor in Lead II; a good lead to assess for "P waves" for optimal viewing of potential heart blocks.
- Support patients who develop symptomatic bradycardia or AV blocks. Your patient may need temporary pacing, and/or IV Atropine to support a slow heart rate resulting decrease in cardiac output.
- Incorporate concepts of contractility, preload, and afterload into bedside assessment.
- Communicate abnormal findings to provider.

Inferior wall STEMI patients are more likely to develop heart blocks and conduction abnormalities.

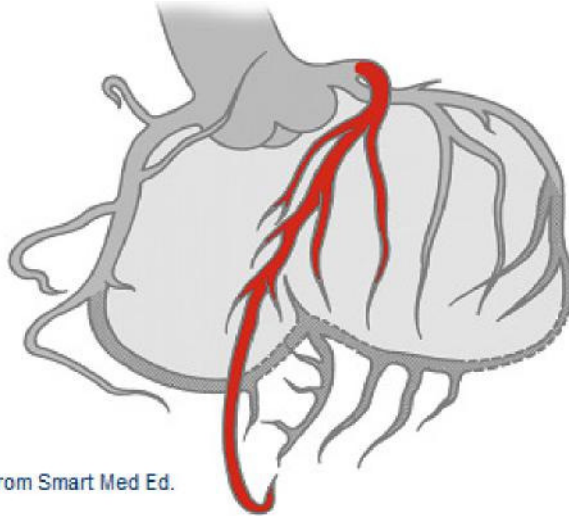
Lead II is the best lead to monitor for P to QRS assessments.



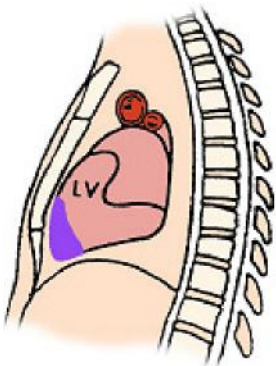
Anterior Wall MI

Coronary Artery Source: Damage to the anterior wall of the left ventricle is typically due to impaired blood flow from the left anterior descending (LAD) coronary artery. Acute anterior wall MIs (AWMI) are a serious form of STEMI since there is acute damage to the left ventricle.

Left Anterior Descending (LAD) Coronary Artery Blood Supply



Used with permission from Smart Med Ed.



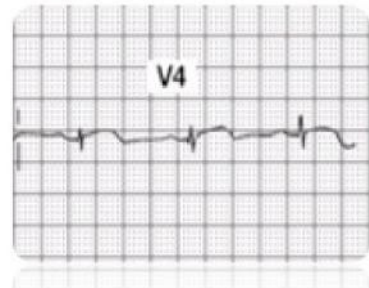
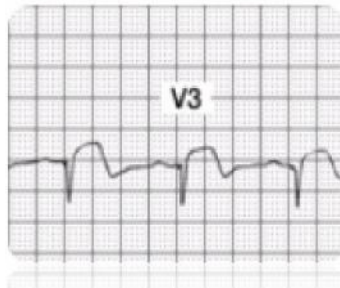
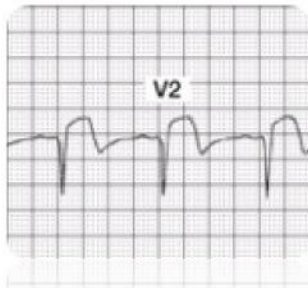
Used with permission from Smart Med Ed.

LAD Supplies blood to:
Anterior wall LV
Interventricular septum
Right Bundle Branch
Anterior division of Left Bundle Branch
Papillary muscles to mitral valve

ECG Findings with Acute Anterior Wall MI

Infarcted tissue on the anterior wall of the ventricular myocardium will no longer depolarize toward the anterior chest wall (where the positive electrodes V1 through V6 are placed). Anterior wall damage is evidenced by abnormal ST segment elevation, followed by development of abnormal Q waves in **leads V1 through V4** (or possibly just V2, V3 and V4). Additionally, many patients lose their R wave voltage in these leads.

Note: To be diagnosed with an acute anterior MI, you must see these **changes in at least two out of the four V1-V4 leads**.



Acute Anterior Wall MI 12 Lead ECG

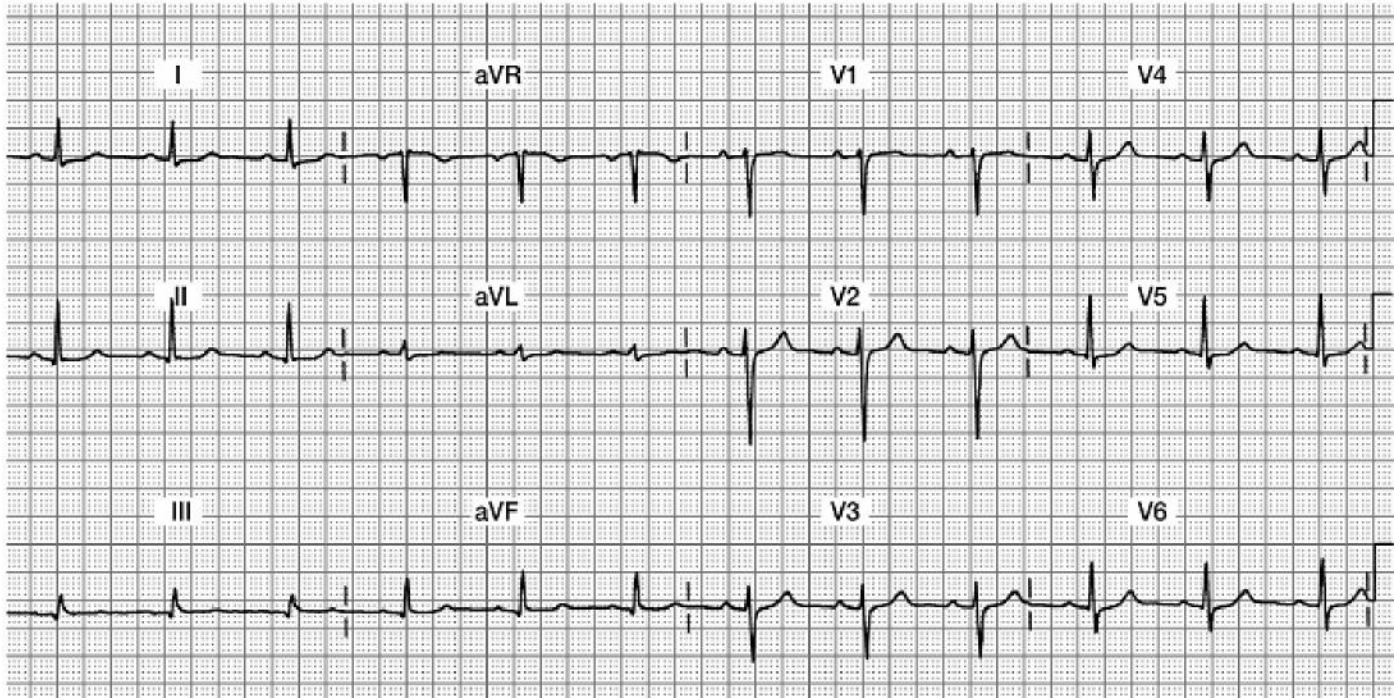
Focus on Leads V1, V2, V3, and V4

Do you see:

Acute ST elevation?

Abnormal Qs?

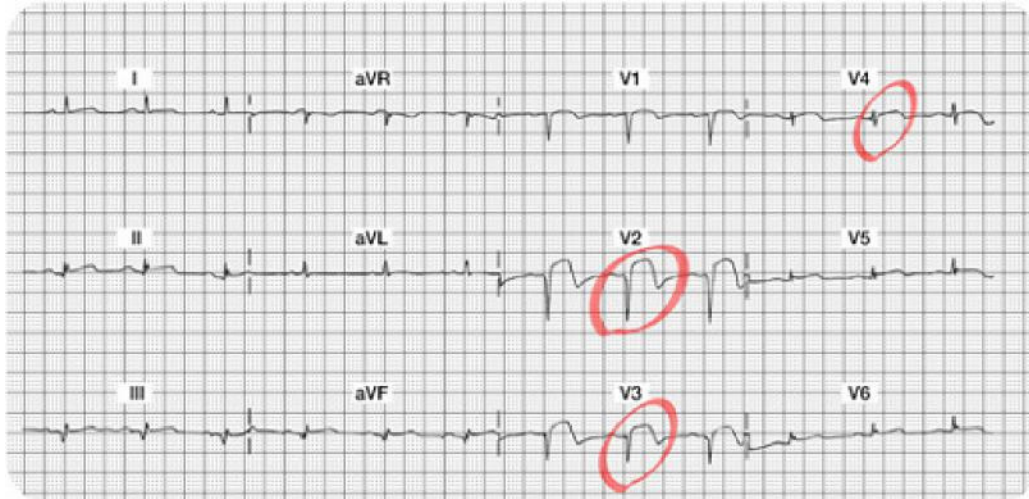
Decreased R wave voltage?



Acute Anterior Wall MI 12 Lead ECG

Do you see the 12 lead ECG abnormalities?

- Acute ST segment elevation in Leads V2, V3, and V4... this is a marker of “acute injury.”
- Abnormal Q’s in V1, V2, and V3 leads... these Q waves are very deep and should be obvious.
- Decreased R wave voltage (as the Q’s grow deeper, the R’s get smaller...all the result of damaged myocardial tissue that is no longer able to conduct a normal impulse). Note there are NO R waves in V1, V2, and V3... and the R wave voltage is also minimal in V4-V6. The patient will be left with permanent Q waves and a lack of “R wave progression.”



Complications of an Anterior Wall MI

The prognosis of patients with anterior wall MI (AWMI) is significantly worse than patients with inferior wall MI. Anterior MI is associated with more myocardial damage than inferior infarction; this damage affects LV function, a major determinant in prognostic outcome after acute MI. An infarction involving 40% or more of left ventricular myocardium is generally associated with cardiogenic shock.

Clinical complications of left coronary artery occlusion include:

- **Pump disturbances:** Weak cardiac output, low BP, weaker pulses, lower urinary output which may lead to CHF. Unless the infarction is massive, signs and symptoms of CHF generally do not occur until a few days after the infarction. However, acute pulmonary edema may occur within the first few hours. Despite advances in medical technology, cardiogenic shock continues to have a high mortality rate.
- **Arrhythmias:** Sinus tachycardia (compensatory mechanism for lower cardiac output), premature atrial contractions (PACs), Second Degree Type II heart block, and premature ventricular contractions (PVCs) which might progress to ventricular tachycardia.
- **BBB:** New bundle branch blocks, either right or left, may result from occlusion to the LAD. You may also know this ECG abnormality as an intraventricular conduction delay (IVCD). When one of the two bundle branches is not conducting normally, the QRS is widened. Notify the provider if you identify a widened QRS. Patients with a bundle branch block may need a pacemaker.

What Do You Think?

The prognosis of patient with an _____ wall type of acute MI is significantly worse than patients with an _____ wall acute MI.

Answer:

Anterior Wall & Inferior Wall

This is because the anterior wall damage involves the left ventricle, which is the main pumping chamber of the heart. Expect a drop in cardiac output.

Management for Acute Anterior Wall STEMI

- Similar to the inferior wall MI patient, the patient may be a candidate for thrombolytic therapy or PCI. If the patient is to receive a thrombolytic, the goal is to administer this drug within 30 minutes of the onset of pain. If the goal is to send the patient to the cath lab for a PCI, the goal is to have this started within 90 minutes of hospital arrival.
- Routine post-MI care: pain relief, stress reduction, oxygen therapy, continuous monitoring for arrhythmias, heart and lung assessments.
- Assess for signs and symptoms of right heart failure, left heart failure or biventricular failure. A third heart sound (S3) is more common in patients with an anterior wall MI than with other types of MIs. In patients with a third heart sound during the acute phase of infarction, the mortality is 40%, as compared with 15% in patients without a third heart sound. A new S3 can indicate ventricular overload and impending pump failure.
- Monitor using the V1 lead. This lead will help you differentiate SVT versus VT as it's likely the patient will be having many ventricular arrhythmias. Patients with AWMIs might also lose blood flow to the Right Bundle Branch (supplied by the LAD coronary artery) and could develop a new RBBB. You can only diagnose a RBBB in leads V1 and V6, thus another good reason to use V1 as your bedside lead!
- Incorporate concepts of contractility, preload and afterload into bedside assessment. For example, has the BP or pulse strength changed? Is the urinary output adequate? Are there any signs of hypovolemia? Are there any changes from baseline peripheral skin circulation assessment?
- Communicate abnormal findings to provider.

Lateral Wall MI

Coronary Artery Source

The left coronary artery splits in to the left circumflex (LCx) and the left anterior descending (LAD) artery. The left circumflex artery supplies the lateral, and sometimes inferior, myocardium. The lateral wall of the heart faces up toward the left shoulder.

Left Circumflex (LCx) Coronary Artery Blood Supply

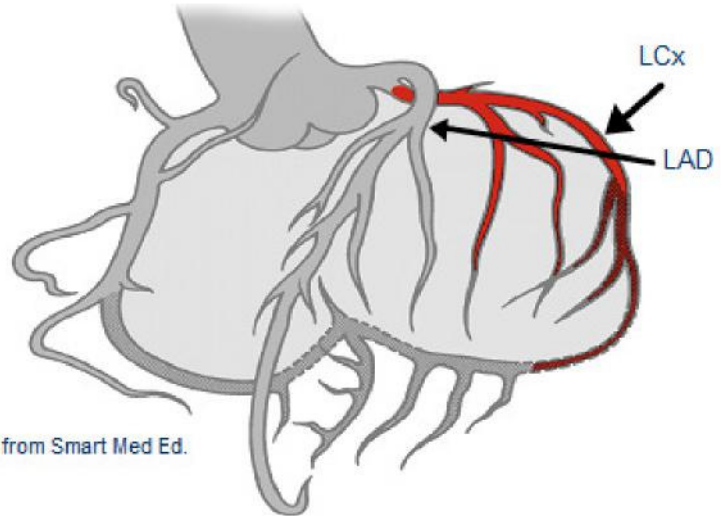
L Circumflex (LCx) supplies blood

to:

Lateral wall LV

Posterior wall LV (10% of population described as "left dominant")

SA Node in 45% of the population



Used with permission from Smart Med Ed.

ECG Findings

The leads which best visualize the lateral wall are Leads **I, aVL**, (“high” lateral wall) V5 and V6 (“low” lateral wall). ST segment elevations, followed by the development of Q waves are typically seen in this setting. Loss of R wave voltage may also be detected.

Note: Abnormal ST elevation and resulting Q waves may be seen in only two of the four leads but this remains diagnostically positive for a Lateral MI. For example, new abnormal ST elevation and abnormal Q waves may be seen in only the high lateral (I, aVL), or in the low lateral (V5, V6), or may be seen in all four leads.

Purely isolated “Lateral MIs” are rare. Typically, lateral MIs are seen in association with anterior MIs resulting in an “Anterior-Lateral MI” or “Inferior-Lateral” infarction.

Knowledge Check 9

ECG changes associated with damage to the anterior surface of the heart are best seen in leads:

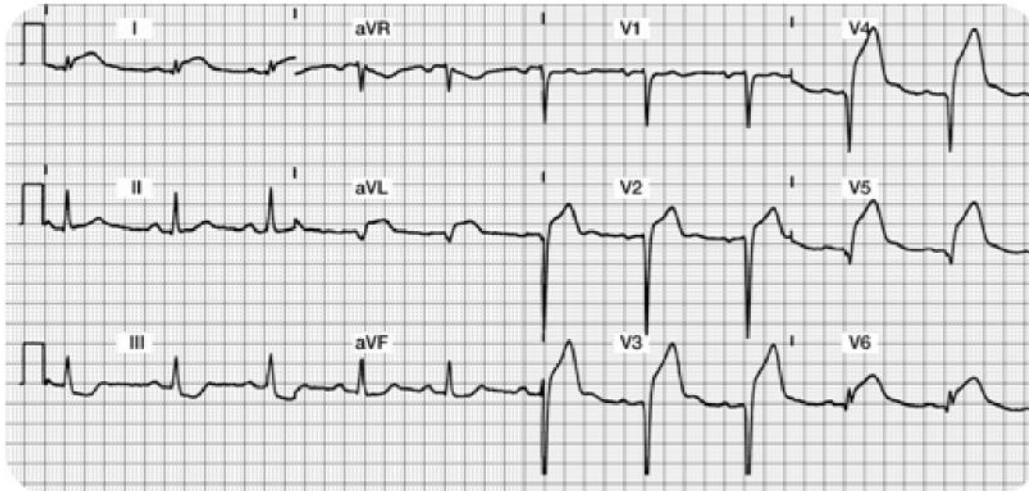
- a. Lead I, aVL, V5, V6- Correct!**
- b. Lead II, aVR, V4, V5
- c. Lead I, aVF, V2, V3

Acute Anterior Lateral Wall MI 12 Lead ECG

Focus on Lateral Leads: I, aVL, V5 and V6 along with Anterior Leads: V1, V2, V3 and V4

Do you see:

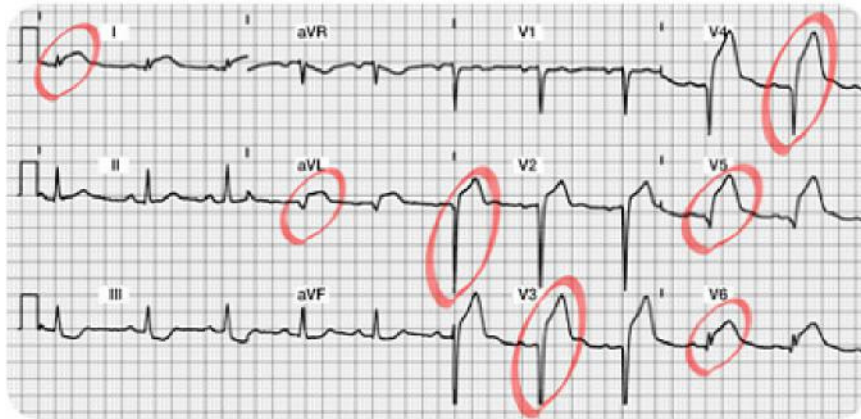- Acute ST elevation?
- Abnormal Q's?
- Decreased R wave voltage?



Acute Anterior Lateral Wall MI 12 Lead ECG Answers

Do you see the 12 Lead ECG abnormalities?

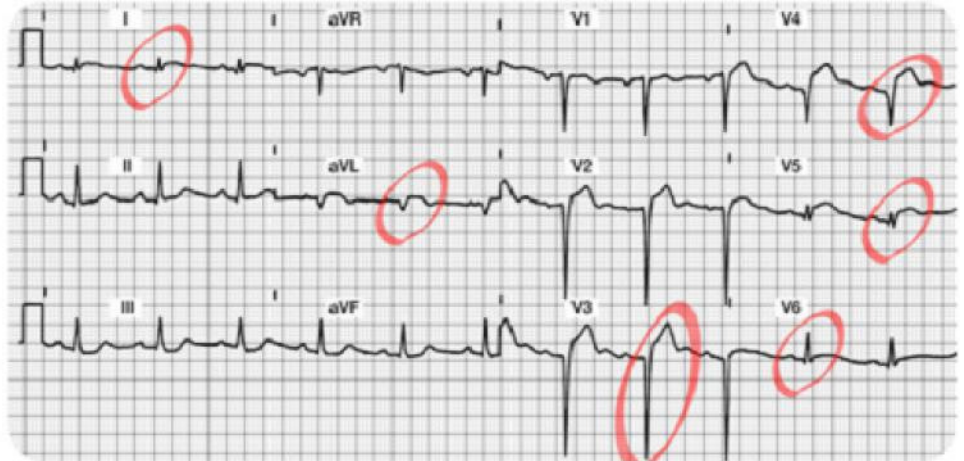- Acute ST segment elevation in Leads I, aVL, V5, and V6 (the lateral leads!!) and also ST elevation in Leads V2, V3 and V4. This demonstrates a large area of “acute injury.”
- Abnormal Q’s in aVL, V2, V3 and V4 leads. These Q waves are ? .04 seconds wide and ? 25% the height of the R wave. As time progresses, the patient may also develop abnormal Q’s in lead I, V5 and V6.
- Decreased R wave voltage...there are NO R waves in V2 – V5. The R wave is also missing in aVL. It looks like the patient will be left with permanent Q waves and a lack of “R wave progression.”



Patient Scenario 1a

A patient with anterior MI (refer to the 12 lead ECG featured on the previous page) is taken to the cardiac catheterization lab for a coronary angiogram. A proximal lesion in the Left Circumflex was discovered with 99% occlusion. The patient underwent a percutaneous coronary intervention (PCI) consisting of a combination percutaneous transluminal coronary angioplasty (PTCA) and the insertion of an intra-coronary stent. The vessel was successfully re-opened.

Pictured is the post-procedure 12 lead ECG taken 30 minutes following the successful revascularization of the Left Circumflex coronary artery.

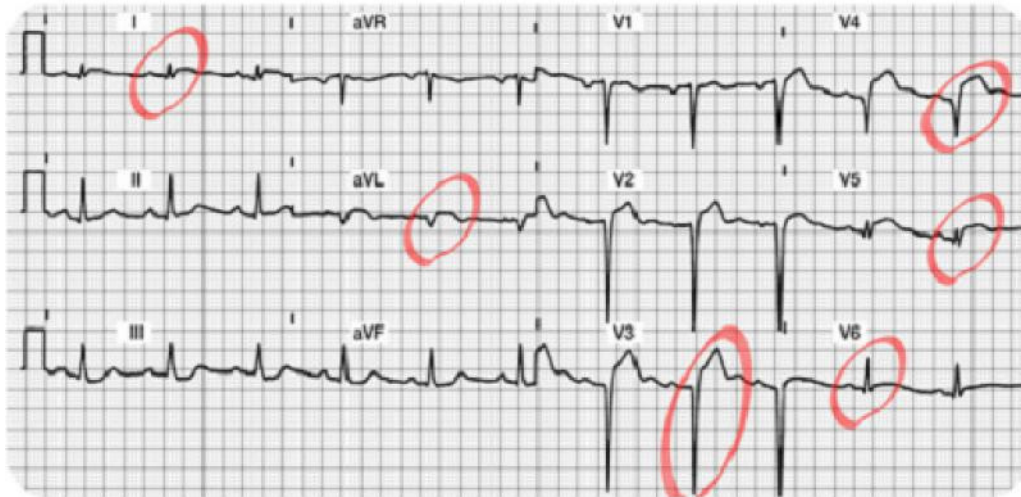

Patient Scenario 1b

Note the dramatic reduction of ST segment elevation in Leads I, aVL, V3, V4, V5 and V6.

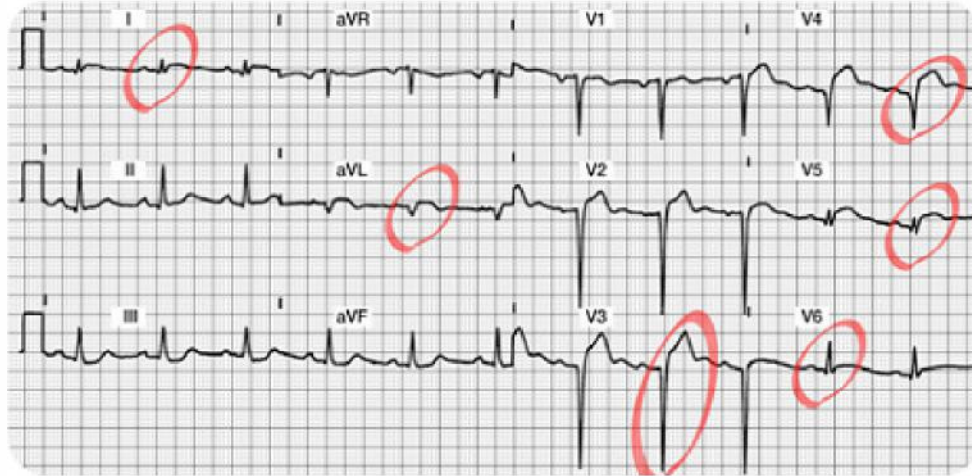If you do not find reduced ST elevation post PCI, notify the MD of this abnormal finding.

As the myocardium is “re-perfused,” expect to find decreased “injury” on the ECG. The patient should be pain free.



Patient Scenario 1c

The ST segments should be trending downward. It may take several days for the ST segments to return to baseline. The patient will likely be left with some permanent abnormal Q waves.



More Information:

You might be wondering, “How much actual myocardial tissue damage was done?” and “Do the Q waves reflect that actual damage really did take place?”

Most cardiologists agree that the two dimensional echocardiogram (2-D Echo) is the best test to fully evaluate the effectiveness of the PCI (or results from a thrombolytic agent). The 2-D echo shows contractility and overall heart function in all four chambers.

Potential Clinical Complications

With the rare isolated “Lateral Infarct,” presenting signs and symptoms are usually benign. This type of MI usually produces minimal hemodynamic complications.

Medical and Nursing Management for acute Lateral Wall Infarctions

- Collaborate with MD for candidacy for thrombolytic therapy or PCI in the cardiac cath lab.
- Routine post-MI care: pain relief, stress reduction, oxygen therapy, continuous monitoring for arrhythmias, heart and lung assessments.
- Best leads to monitor: any of the **lateral leads (I, V5 and V6 are best)**.
- Incorporate concepts of contractility, preload and afterload into assessment.
- Communicate abnormal findings to MD.

This table summarizes the best leads for detection of acute myocardial abnormalities.

Type of Myocardial Infarction	Best Leads
Inferior Wall	II, III, aVF
Anterior Wall	V1, V2, V3, V4
Lateral Wall	I, aVL, V5, V6
Anterior Lateral Wall	I, aVL, V5, V6, V1-V4

STEMI ECG Interpretation Format or Recipe

It is now time to practice your new skills. Try using this “format” to interpret your 12 lead ECGs. Remember, if you follow a systematic approach, your success rate will be enhanced!

Step 1. **Assess the Lateral Leads (I, aVL, V5, and V6).**

Begin with Lead I. Look for normal or abnormal Q waves. Is the ST segment on the baseline? If not, is it depressed/inverted (e.g. ischemia) or elevated (e.g. injury).

Is there an R wave in every lead (except aVR, which we are ignoring)?

Continue to look at all of the Lateral Leads as if they were a family grouping. Examine leads I, aVL, V5 and V6 again. Do you find changes in at least two of the four leads? Continue to examine the Q, R, and ST segments.

Write down your “summary of the lateral wall”... You are now ready to progress and evaluate the inferior wall.

Step 2. **Assess the Inferior Leads (II, III, aVF).**

Look for normal or abnormal Q waves.

Is there an R wave in all three leads? (There should be although the amplitude in lead III and aVF may be small).

Is the ST segment on the baseline? If not, is it depressed/inverted (e.g. ischemia) or elevated (e.g. injury).

Look at the inferior leads as a family. You must find changes in at least two out of three leads.

Step 3. **Examine the Anterior Leads (V1-V4).**

Are there any abnormal Q waves?

Do you see upright R waves in all leads? Do the R waves grow or become progressively larger in amplitude? (they should).

Are the ST segments on the baseline in all leads except V1 which is biphasic? Evaluate the anterior leads as a family. Are there changes or abnormalities in at least two of the four leads?

Good Job!! Now you are ready to prioritize and summarize!

Step 4. **Identify Acute Injury** (if present).

This is the most dangerous and requires immediate attention.

Remember acute injury is characterized by ST segment elevation which must be seen in the majority of the “lead groupings” (e.g. ST elevation seen in two thirds of the inferior leads II, III, and aVF).

Step 5. **Identify Patterns of Ischemia** (if present).

Remember ischemia is recorded as ST or T wave inversion. This typically reflects an inadequate oxygen supply to meet the myocardial demands.

This is an opportunity to intervene and prevent a transmural or STEMI.

Step 6. **Identify any “old” acute MI patterns.**

Old MIs are permanently recorded on the **ECG as abnormal Q waves with normal ST segments and T waves.** The wide and deep Q's will never go away.

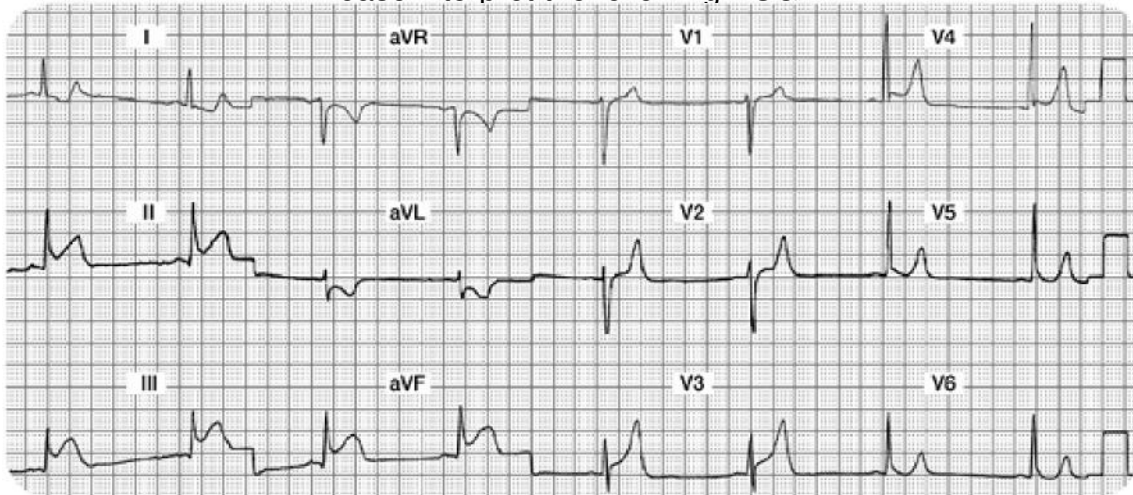
Remember that loss of R wave voltage may also be seen in these same leads.

Let's Practice!!

Case Study One

Mr. A is admitted to your unit with the diagnosis of chest pain, rule out MI. He is currently pain free with stable vital signs. After returning from the bathroom, he complains of severe indigestion in the retrosternal area of his chest. He rates his "indigestion" as a 9 on a scale of 0 - 10. Mr. A tells his nurse he is very scared. He is diaphoretic and his initial vital signs are **88/58, RR 20**.

Please interpret the following ECG:



Your 12 Lead Worksheet:

Summary of the Lateral Leads (I, aVL, V5, and V6):

Summary of the Inferior Leads (II, III, aVF):

Summary of the Anterior Leads (V1, V2, V3, V4):

Interpretation:

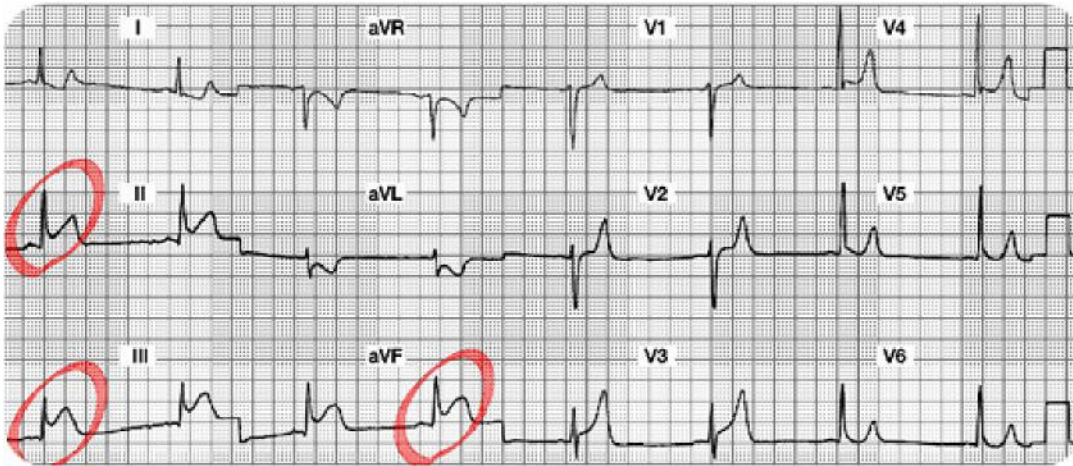
Which coronary artery is probably occluded?

What potential complications are you looking for?

What bedside lead should you select to monitor this patient?

What are your nursing priorities?

Case Study One: 12 Lead Worksheet Answers



Summary of the Lateral Leads (I, aVL, V5 and V6):

Lead I and aVL have ST segment depression (? Ischemia). Leads V5 and V6 are normal. All Lateral leads do not have abnormal Q waves.

Summary of the Inferior Leads (II, III, aVF): ST elevation in all three leads. No abnormal Q waves.

Summary of the Anterior Leads (V1, V2, V3, V4): Good R wave progression. No abnormal Q waves. ? ST segment elevation in V3 and V4 versus large T waves throughout the anterior leads.

Interpretation: Acute Inferior Wall STEMI (or injury).

(We will keep an eye on the ST segments in V3 and V4, but the predominant problem lies with the inferior wall.)

Which coronary artery is probably occluded? Right Coronary Artery

What potential complications are you looking for?

Conduction abnormalities such as heart blocks, and/or damage to the Right Ventricle.

What bedside lead should you select to monitor this patient? Lead II

What are your nursing priorities?

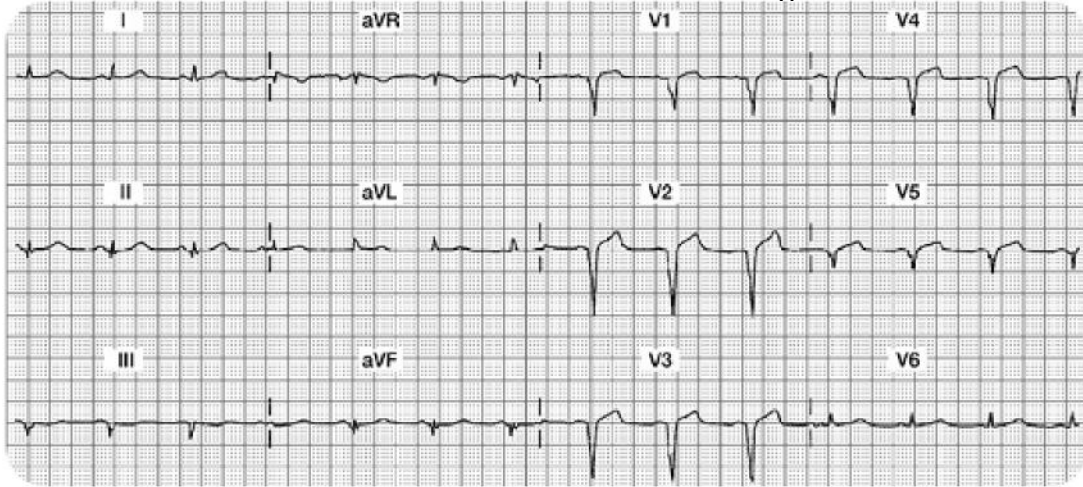
Relieve chest pain by decreasing myocardial oxygen consumption (e.g. rest) and increase oxygen supply (e.g. aspirin, oxygen, nitrates, morphine, etc).

Consult with MD regarding candidacy for either a) systemic IV thrombolytic medication or b) a trip to the cath lab for PCI.

Case Study Two

Mrs. B. is transferred to your unit from acute care with new onset chest discomfort. Her hemodynamics are stable. Cardiac marker lab results are pending.

The 12 lead ECG shows the following:



Your 12 Lead Worksheet:

In this setting, would you expect the cardiac marker labs to be positive or negative?

What bedside lead should you select to monitor this patient?

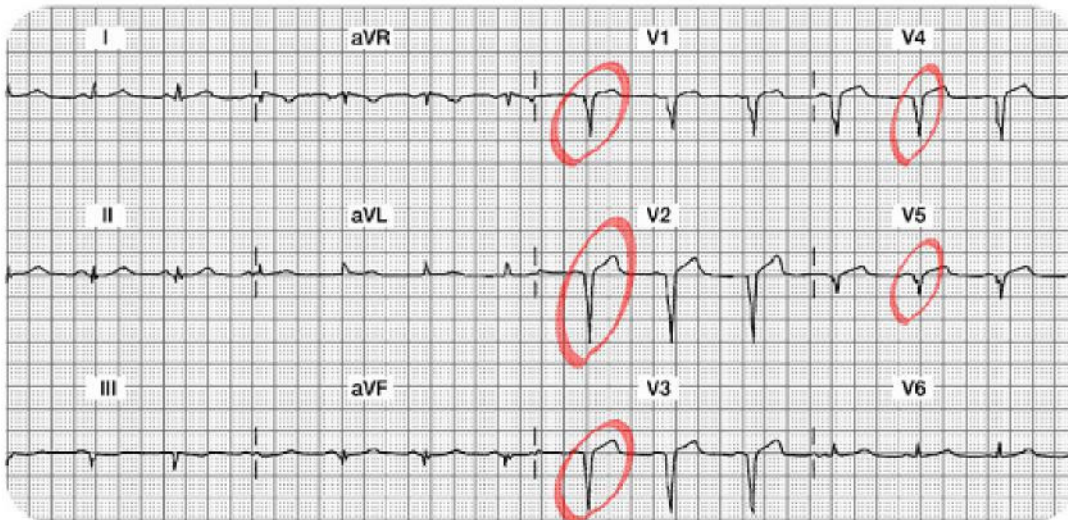
What are your nursing priorities?

Summary of the Lateral Leads (I, aVL, V5, and V6):

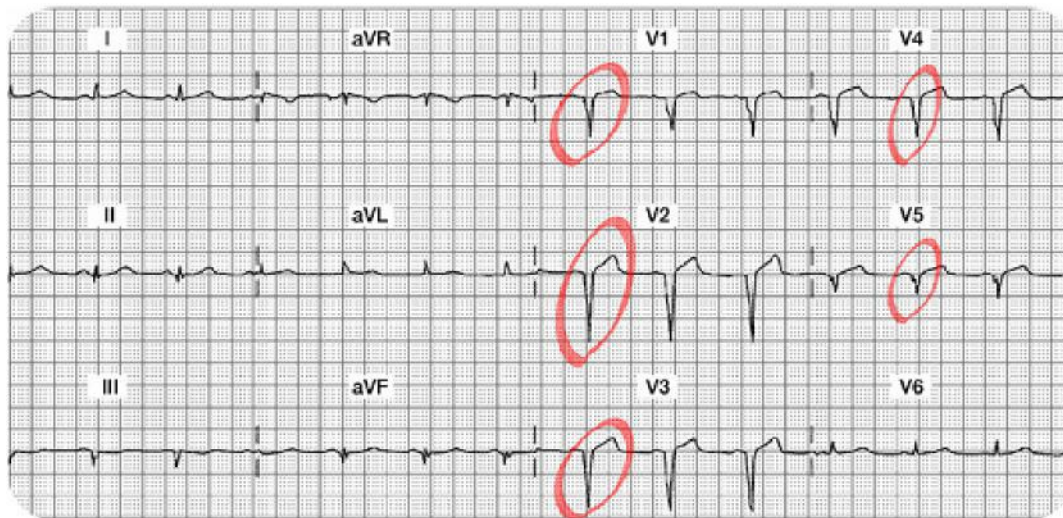
Summary of the Inferior Leads (II, III, aVF):

Summary of the Anterior Leads (V1, V2, V3, V4):

Interpretation:



Case Study Two: 12 Lead Worksheet Answers



Summary of the Lateral Leads (I, aVL, V5 and V6): Leads I and aVL both have a normal ST segment on the isoelectric line. T waves are normal. V5 is has an abnormal Q wave but normal ST segment. The R wave is also missing in V5. V6 has a normal ST segment and no abnormal Q waves.

Summary of the Inferior Leads (II, III, aVF): All three leads are a bit difficult to evaluate because they are small in size. Lead II has a normal small Q wave, a small upright R wave and a normal ST segment and T wave. Lead III has an abnormal QS morphology, loss of R wave and a flat versus slightly inverted T wave. Lead aVF has a small (normal) Q, small R wave and normal ST segment and T wave.

Summary of the Anterior Leads (V1, V2, V3, V4): V1, V2, V3 and V4 do not have any R waves. Instead, there are abnormal Q waves in all four leads or otherwise called a QS morphology. The ST segment and T waves are normal.

Interpretation: Old (chronic) Anterior Wall MI. This MI is “old” because in addition to the permanent Q waves, the ST segment, and T waves are normal.

In this setting, would you expect the cardiac marker labs to be positive or negative?
“Negative” since this is an old MI and no acute changes are noted

What bedside lead should you select to monitor this patient? Since there are no acute changes, any bedside lead is acceptable.

What are your nursing priorities?

Compare this 12 lead to a previous 12 lead from an old chart. Look to see if these abnormal Q waves were there before.

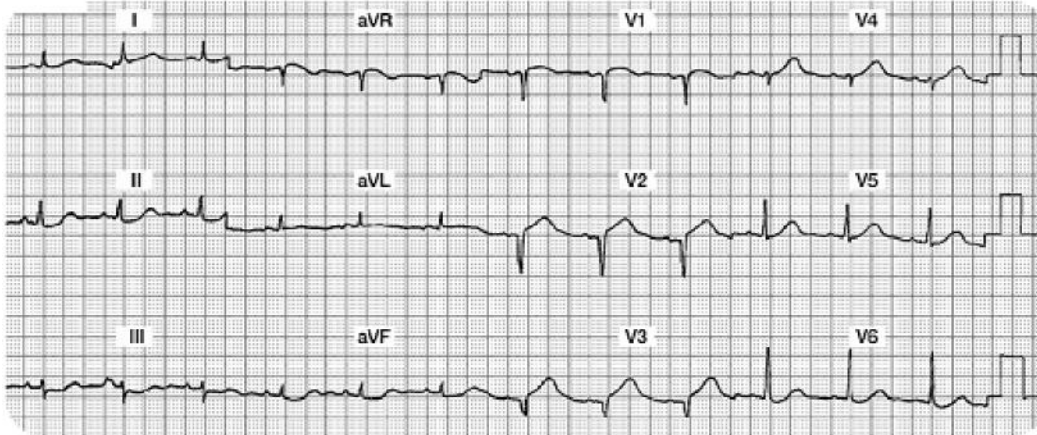
Monitor cardiac makers to be sure this is all old stuff.

Search for other possible causes of this chest discomfort.

Confirm that there is no new damage.

Case Study Three

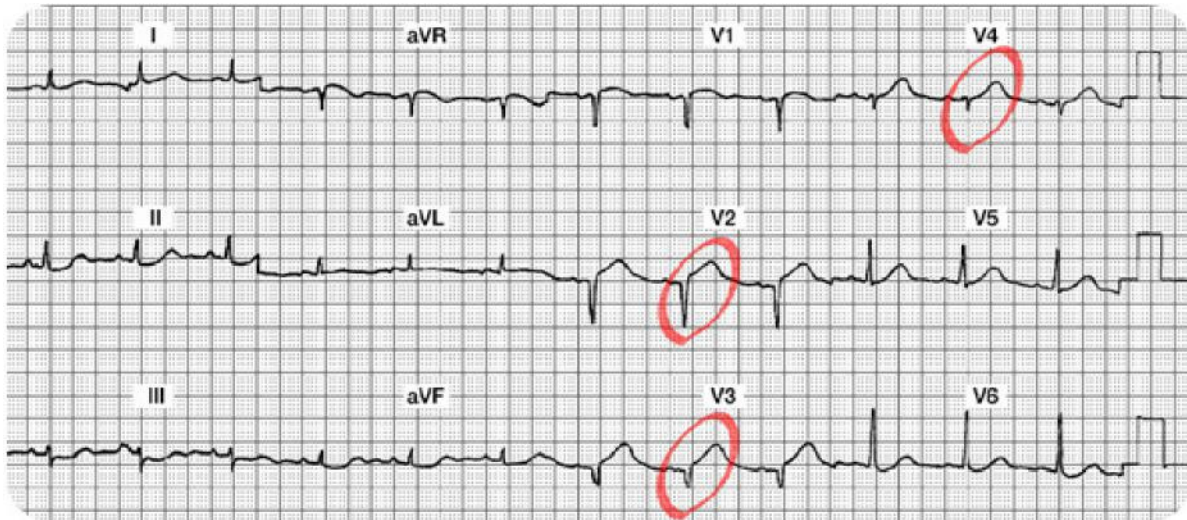
Two hours after returning from the cath lab status post intracoronary stent insertion to his LAD, Mr. W. c/o chest and left arm discomfort. You administer oxygen and sublingual NTG per unit protocol and obtain the following 12 lead ECG:



Your 12 Lead Worksheet:

1. Which coronary artery is probably occluded?
2. What bedside lead should you select to monitor this patient?
3. What are your nursing priorities?
4. Summary of the Lateral Leads (I, aVL, V5, and V6):
5. Summary of the Inferior Leads (II, III, aVF):
6. Summary of the Anterior Leads (V1, V2, V3, V4):
7. Interpretation:

Case Study Three: 12 Lead Worksheet Answers



Summary of the Lateral Leads (I, aVL, V5 and V6): Leads I, aVL, V5 and V6 are all normal. There are no abnormal Q waves, no ST-T abnormalities. There is a wandering baseline in Lead I (making it a bit more difficult to read... remind the patient to lie very still when the 12 Lead ECG is being recorded).

Summary of the Inferior Leads (II, III, aVF): All three inferior leads have small complexes and there is a wandering baseline or artifact (making it harder to read). However, there are no abnormal Q waves, normal R waves (small, but present), and the ST-T segments and waves appear normal.

Summary of the Anterior Leads (V1, V2, V3, V4): V1 might have a small R wave, but it is difficult to see. The ST-T in V1 looks normal. V2 and V3 are missing their R waves and both have abnormal Q waves with new ST segment elevation. V4 has a small R wave and a small amount of ST elevation.

Interpretation: New Anterior STEMI or acute anterior wall MI

Which coronary artery is probably occluded? The LAD feeds the anterior surface of the myocardium.

What bedside lead should you select to monitor this patient?

V1. In this lead you can monitor for changes in ST segments, potential new right bundle branch block, and can use ECG criteria to differentiate potential Supraventricular Tachycardia (SVT) versus Ventricular Tachycardia (VT).

What are your nursing priorities?

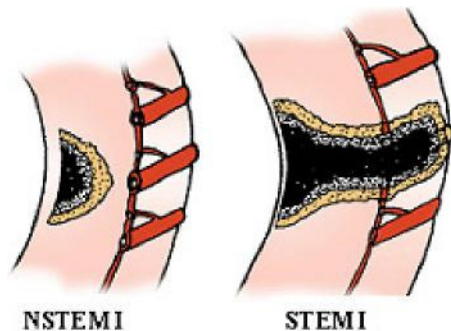
Relieve chest pain by decreasing myocardial oxygen consumption (e.g. rest) and increase oxygen supply (e.g. oxygen, nitrates, morphine, etc).

Consult with MD regarding candidacy for either a thrombolytic or PCI.

Non ST Elevation Myocardial Infarctions

Thus far, this module has focused on patient experiencing a ST elevation MI. This type of infarction was previously called a “transmural” MI, but newer terminology is now used, so it is called “STEMI”. As we know, most patients with this disease process have damage through all layers of the myocardium. With a STEMI, patients will have both ST elevation in select leads and positive (or abnormal) cardiac marker lab results.

There is a second type of acute infarct which is now called a “Non-ST elevation MI” (NSTEMI). This patient is also having a myocardial infarction, but it may not be through all layers of the myocardium. In this setting, patients will also have positive cardiac lab results, but they will not show ST elevation.



The illustration on the left depicts a NSTEMI. Note the cross section of the ventricle from the epicardium to the endocardium and an area of non-transmural necrosis. The illustration on the right depicts a cross section of the ventricle with transmural damage (all layers) resulting in a STEMI.

Used with permission from Smart Med Ed.

Pathophysiology

The Non ST elevation MI (NSTEMI) is most often the result of reduced myocardial perfusion that results from coronary artery narrowing. The narrowing is usually caused by a non-occlusive thrombus that developed on a disrupted atherosclerotic plaque. Microembolization of platelet aggregates and components of the disrupted plaque are believed to be responsible for the release of myocardial cardiac lab markers (e.g. elevation of CK, CK-MB, Troponin I).

ECG Abnormalities of a Non ST Elevation MI (NSTEMI)

The NSTEMI does not have ST elevation on the 12 lead ECG. Instead, they have **ST-T wave changes similar to the patient with transient ischemia**. We see ST segment depression and/or T wave inversion on the 12 lead ECG. The ST segment depression and/or flipped T waves are sometimes seen in “regional” areas (example: T wave inversion seen in Leads II, III and aVF) or they may be detected in “global” areas (example: T wave inversion seen in inferior, anterior and lateral leads).

Another ECG difference in this patient population is the absence of abnormal Q waves along with normal R waves. The NSTEMI patient does not lose their R wave voltage and does not develop Q waves on the ECG.

What Do You Think?

A person with a NSTEMI will have ST – T wave abnormalities and positive cardiac marker lab results.

True- Correct!

False

Test Yourself:

A person with a NSTEMI will benefit from an IV thrombolytic.

True

False- Correct!

Summary of ECG Changes with NSTEMI

- Regional or Global ST segment depression and/or T wave inversion
- No abnormal Q waves
- No loss of R wave voltage
- Elevated cardiac marker labs (CK-MB, Troponin I)

Knowledge Check 10

A person with a NSTEMI will eventually develop abnormal Q waves reflecting an old or chronic MI.

- a. True- Incorrect! NSTEMI patients do not typically develop Q waves. The formations of Q waves are in conjunction with STEMI patients.
- b. **False- Correct!**

Treatment Modalities for NSTEMI

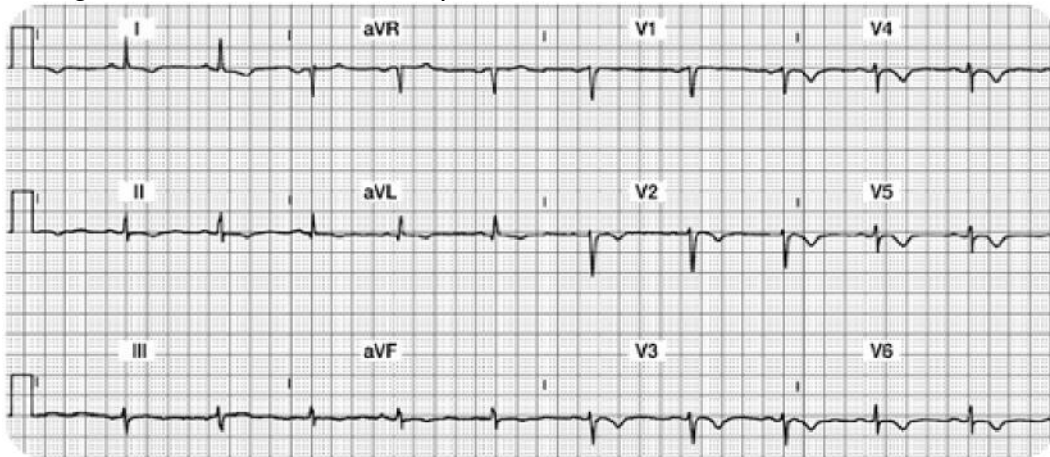
Studies have shown that thrombolytic therapy is of little benefit in the NSTEMI patient. According to the American College of Cardiology, treatment guidelines have been inconsistently implemented, resulting in inconsistent medical practices for the NSTEMI patient. Nurses must be knowledgeable in understanding how the treatment guidelines differ between the STEMI and NSTEMI patient populations (Amsterdam, Wenger, Brindis, Casey, Ganiats, Holmes, ... & Zieman, 2014).

Treatment Priorities For The NSTEMI Patient

- Prompt antiplatelet therapy. Aspirin is best, but an Adenosine Diphosphate Receptor Inhibitor (ADP) will likely be given if patient is allergic to aspirin. Some ADP inhibitors include:
 - Clopidogrel (Plavix)
 - Prasugrel (Effient)
 - Ticagrelor (Brilinta)
 - Ticlopidine (Ticlid)
- Heparin or Low Molecular Weight Heparin may be used on a short term basis.
- Administer an IV platelet glycoprotein (GP) IIB-IIIa inhibitor which includes:
 - Abciximab (ReoPro)
 - Eptifibatid (Integrilin)
 - Tirofiban (Aggrestat)
 - This category of medication helps to inhibit platelet aggregation and has been shown to lower death rates in the NSTEMI population.
- A beta blocker is initiated unless contraindicated.
- Add an angiotension-converting enzyme (ACE) inhibitors or angiotension-receptor blocker (ARB) if the patient has high blood pressure, signs of heart failure, diabetes, or abnormal ejection fraction.
- Cardiac catheterization is indicated only if the patient is unstable, otherwise is generally not necessary.
- At discharge, statins should be added to the regimen.

Case Study 4

Mr. H. has a history of COPD and chronic renal insufficiency requiring hemodialysis. He puts on his call light complaining of chest, back, and arm pain. You obtain a 12 lead ECG.



Case Study Worksheet

Your 12 Lead Worksheet:

Summary of the Lateral Leads (I, aVL, V5 and V6):

Summary of the Inferior Leads (II, III, aVF):

Summary of the Anterior Leads (V1, V2, V3, V4):

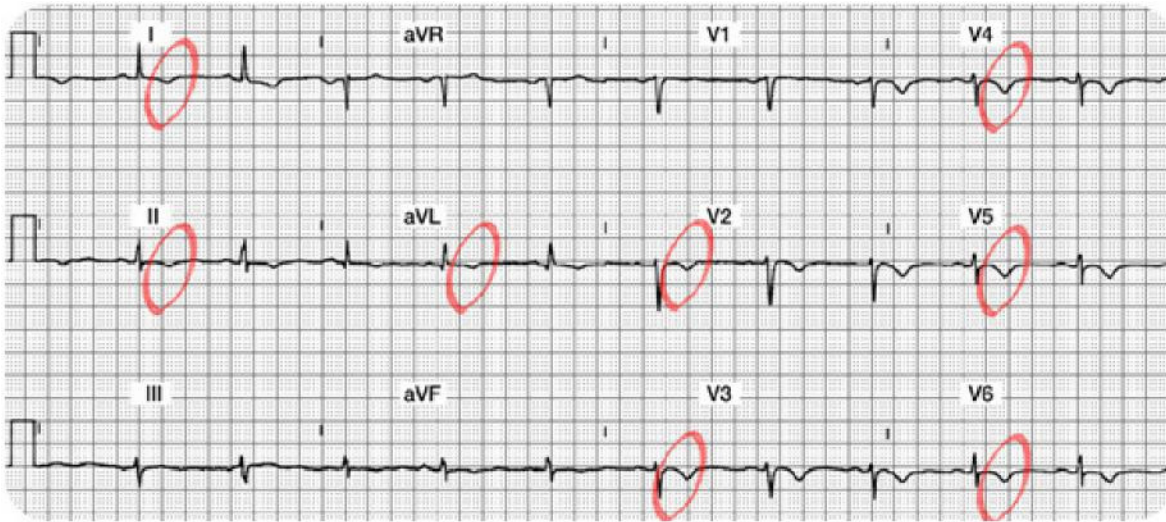
Interpretation:

Which coronary artery is probably occluded?

What bedside lead should you select to monitor this patient?

What are your nursing priorities?

Case Study 4 Lead Worksheet Answers



Summary of the Lateral Leads (I, aVL, V5 and V6): In Lead I, there is a normal Q and R wave. The ST segment is slightly depressed and the T wave is inverted. In aVL, the Q, R and ST segments are normal, but the T wave is inverted. V5 and V6 have R waves (a bit small, but present nonetheless). Both leads have T wave inversion.

Summary of the Inferior Leads (II, III, aVF): All three leads are normal EXCEPT they have inverted T waves.

Summary of the Anterior Leads (V1, V2, V3, V4): V1 is normal. V2-V4 have no abnormal Q waves, R waves (a bit small and not really “progressing”), but all 3 leads have T wave inversion.

Interpretation: Diffuse ischemia versus a Non-ST elevation MI (NSTEMI). How do you diagnose ischemia versus NSTEMI? Look at the cardiac marker labs. If they are positive, this is a NSTEMI. If they are negative (and especially if these T wave inversions are transient), it is ischemia. This is tricky as both ischemia and NSTEMI look alike. The lab results will guide your diagnosis.

Which coronary artery is probably occluded? Not easy to predict as changes are diffuse and found in many leads.

What bedside lead should you select to monitor this patient? A combination of Lead II and V1 should cover most potential events.

What are your nursing priorities?

- Relieve chest pain by decreasing myocardial oxygen consumption (e.g. rest) and increase oxygen supply (e.g. oxygen, nitrates, morphine, etc.).
- Closely monitor serum cardiac marker lab results. If the markers are negative, the T wave inversion is likely to be from ischemia. If the markers are positive for damage, these T waves are likely a clue that this patient is having a NSTEMI. Remember that NSTEMI patients have not been shown to benefit from thrombolytic therapy. Treatment for NSTEMI will include aspirin, heparin, and possibly a IIB/IIIA platelet inhibitor.

Conclusion

Rapid assessment and treatment of acute myocardial infarction is key for initiation of appropriate therapy and preserving myocardial tissue. This module provided the nurse caring for the acute MI patient with a systematic system to examine the 12-lead ECG to determine acute or chronic changes.

The module has focused on identification and management of acute ischemia, injury, and infarction with an emphasis on STEMI patterns to the inferior, anterior, and lateral surfaces of the heart. Infarct types were correlated to the coronary artery blood supply with an understanding of potential complications resulting from each STEMI infarct. Non-ST elevation myocardial infarction (NSTEMI) patterns and treatments were also reviewed. Due to the complexity of this material, the learner is encouraged to routinely practice the knowledge learned in this module.

References

AHRQ, 2011. Acute myocardial infarction: median time from hospital arrival to primary PCI in acute myocardial infarction (AMI) patients with ST-segment elevation or LBBB on the ECG performed closest to hospital arrival time. Retrieved July 15, 2011 from <http://www.qualitymeasures.ahrq.gov/content.aspx?id=49143>

Amsterdam, E. A., Wenger, N. K., Brindis, R. G., Casey, D. E., Ganiats, T. G., Holmes, D. R., ... & Zieman, S. J. (2014). 2014 AHA/ACC guideline for the management of patients with non-ST-elevation acute coronary syndromes: a report of the American College of Cardiology/American Heart Association Task Force on Practice Guidelines. *Journal of the American College of Cardiology*, 64(24), e139-e228.

Medline. (2015). Unstable angina. Retrieved from <https://www.nlm.nih.gov/medlineplus/ency/article/000201.htm>

Mozaffarian, D., Benjamin, E. J., Go, A. S., Arnett, D. K., Blaha, M. J., Cushman, M., ... & Stroke, S. S. (2015). Heart disease and stroke statistics-2015 update: a report from the american heart association. *Circulation*, 131(4), e29.

National Heart, Lung and Blood Institute, 2015. Disease Statistics. Retrieved from <http://www.nhlbi.nih.gov/about/documents/factbook/2012/chapter4>

At the time this course was constructed all URL's in the reference list were current and accessible.rn.com is committed to providing healthcare professionals with the most up to date information available.

© Copyright 2003, AMN Healthcare, Inc.

Disclaimer

RN.com strives to keep its content fair and unbiased. The author(s), planning committee, and reviewers have no conflicts of interest in relation to this course. There is no commercial support being used for this course. Participants are advised that the accredited status of RN.com does not imply endorsement by the provider or ANCC of any commercial products mentioned in this course. There is no "off label" use of drugs or products discussed in this course.

You may find that both generic and trade names are used in courses produced by RN.com. The use of trade names does not indicate any preference of one trade named agent or company over another. Trade names are provided to enhance recognition of agents described in the course.

Note: All dosages given are for adults unless otherwise stated. The information on medications contained in this course is not meant to be prescriptive or all-encompassing. You are encouraged to consult with physicians and pharmacists about all medication issues for your patients.

IMPORTANT INFORMATION:

This publication is intended solely for the educational use of healthcare professionals taking this course from [RN.com](https://www.rn.com) in accordance with [RN.com terms of use](https://www.rn.com/terms-of-use). The guidance provided in this publication is general in nature, and is not designed to address any specific situation. As always, in assessing and responding to specific patient care situations, healthcare professionals must use their judgment, as well as follow the policies of their organization and any applicable law. Organizations using this publication as a part of their own educational program should review the contents of this publication to ensure accuracy and consistency with their own standards and protocols. The contents of this publication are the copyrighted property of [RN.com](https://www.rn.com) and may not be reproduced or distributed without written permission from [RN.com](https://www.rn.com).

Healthcare providers, hospitals and healthcare organizations that use this publication agree to hold harmless and fully indemnify [RN.com](https://www.rn.com), including its parents, subsidiaries, affiliates, officers, directors, and employees, from any and all liability allegedly arising from or relating in any way to the use of the information or products discussed in this publication.